

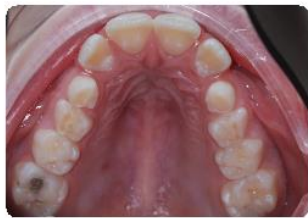Molly Morris

1. Non-Extraction Treatment
2. .022 x .028 Innovation Brackets, Cervical Headgear, Expansion Herbst Appliance, Class II elastics, Vertical finishing elastics
3. Initial early treatment utilized upper 2x4 bracketing with cervical pull headgear. Headgear was continued with upper Hawley use (inadequate headgear wear). Phase 2 was initiated with an expansion Herbst appliance. Upper brackets were placed after expansion was discontinued and lower brackets were placed when Herbst was discontinued. Class II elastics were used to maintain Class II correction and vertical elastics were used for final settling.

Case Classification, Timeline, and Retention

Case # 1

Beginning Age	11 yrs. / 6 mos.
Angle Classification	Class II division I
Date Begun (Phase 1)	1-4-12
End of Phase 1	8-7-12
Phase 1 treatment time	7 months
Date Begun (Phase 2)	2-27-14
Date Finished	7-14-16
Phase 2 treatment time	2 yrs. / 5 mos.

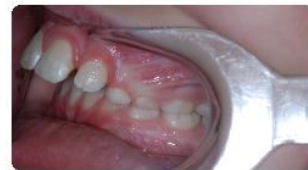
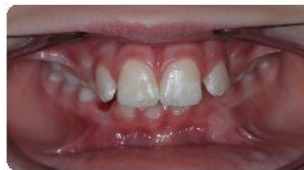
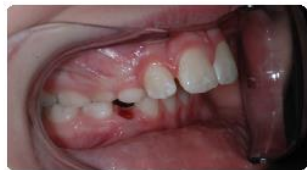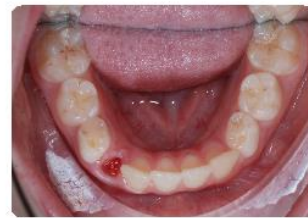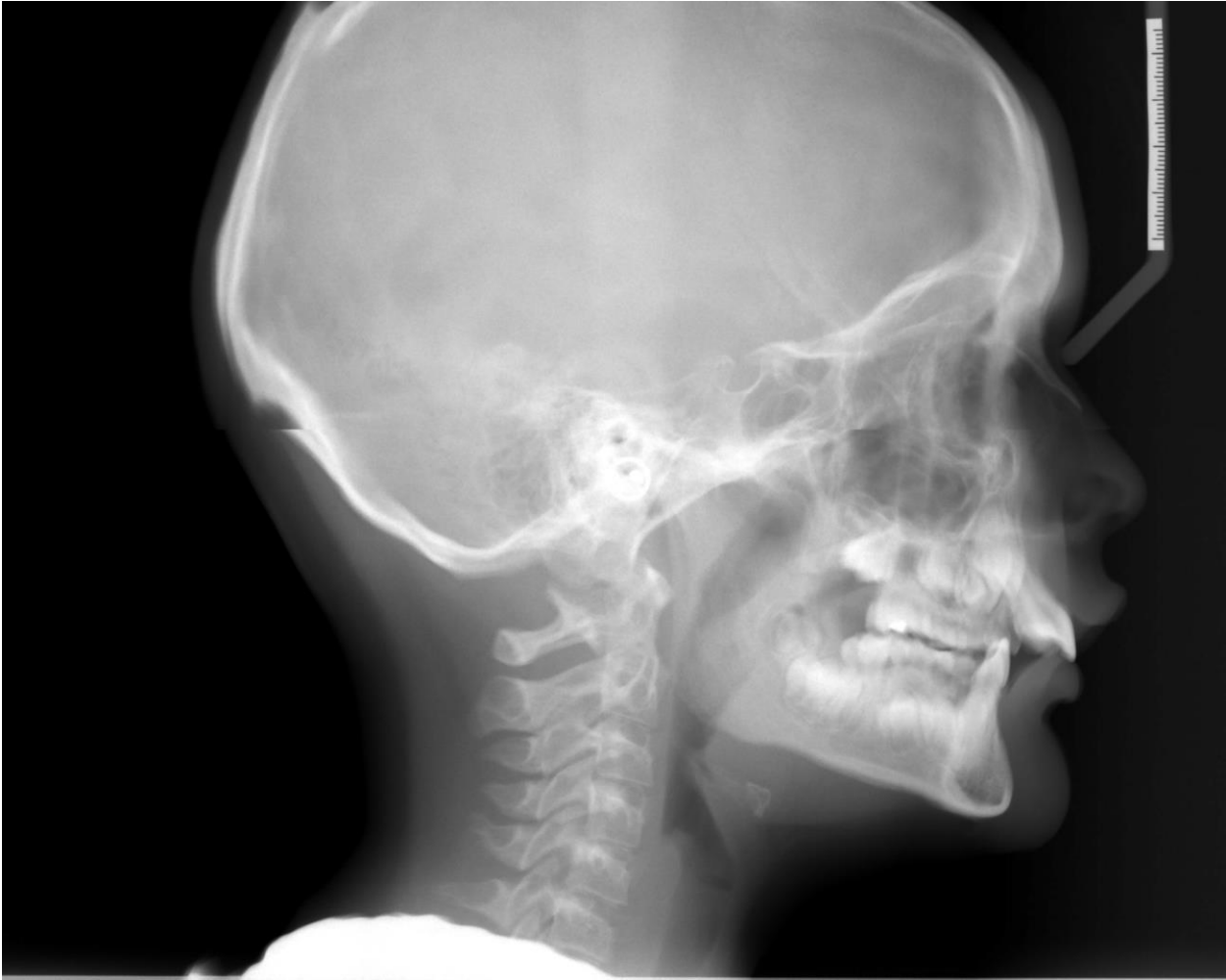Molly Morris
12/20/2011, Initial, YR. 8 MO. 5

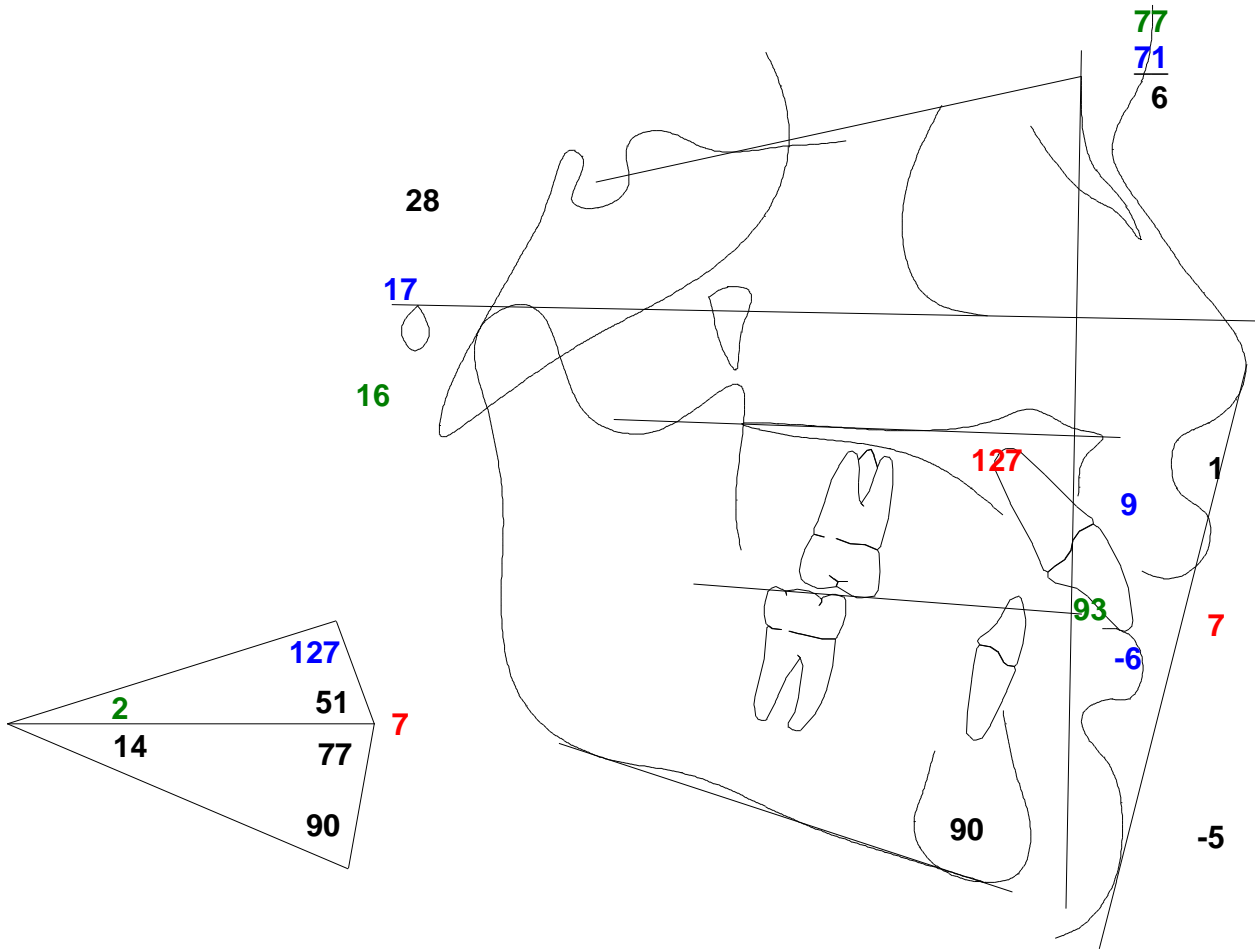


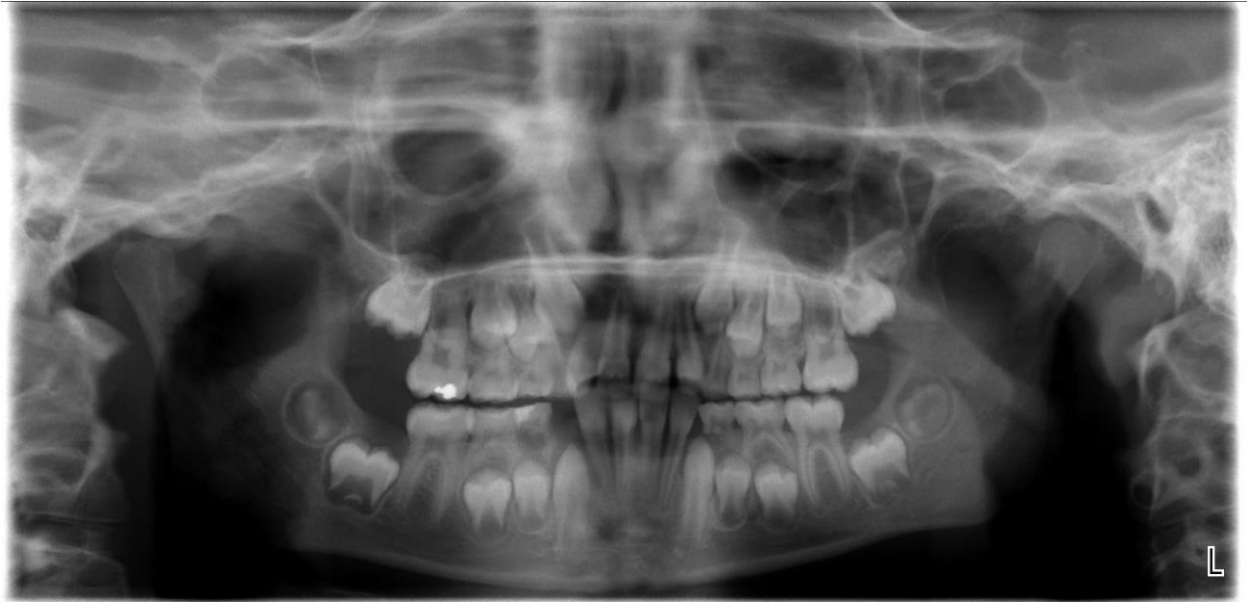Mark S. Geller, DDS, MSD, PA
www.gellerorthodontics.com

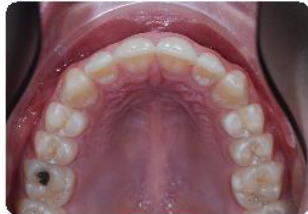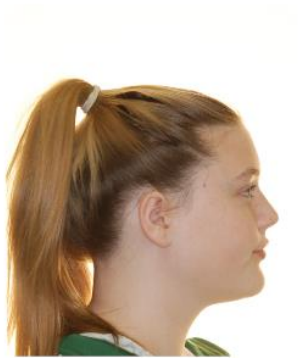1220 Coit#108 | Plano, Texas 75075 | (972) 696-4502











Molly Morris
10/10/2016, Final, YR. 13 MO. 3



Mark S. Geller, DDS, MSD, PA
www.gellerorthodontics.com

1220 Cot#108 | Plano, Texas 75075 | (972) 596-4502





