



Aaron J. White

Extraction + Mutilated

San Antonio, TX

January 26-29, 2017



Jenifer Shultz

Case Description Summary

Extraction + Mutilated

.022 MBT Rx GAC In-Ovation R (self-ligating)

Missing #4, 11

Extract #1, 21, 29

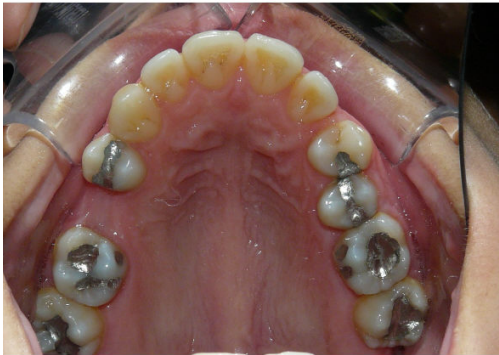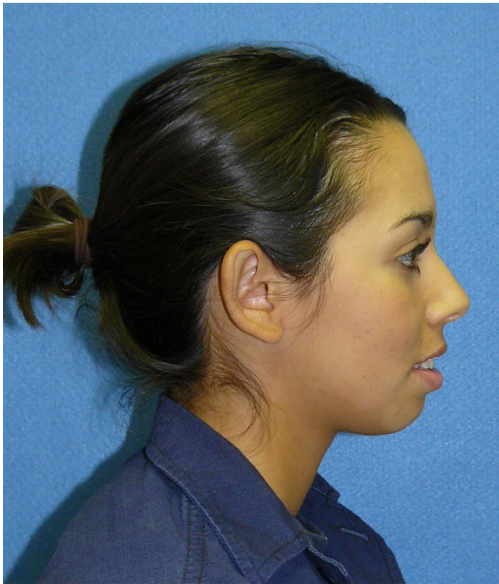
Canine substitution #12

Differential anchorage (maximum anchorage UR; minimum anchorage UL; reciprocal Md anchorage)

Class II elastics to finish

Case Classification, Timeline, and Retention Details

Case #	#1
Beginning age	20-5
Angle Class	Class I
Date Begun	Diagnosis: 11-03-2008 / Braces placed: 12-01-2008
Date Finished	08-13-2010
Treatment Time	20 months
Type of Retention	Maxillary Hawley Mandibular Hawley



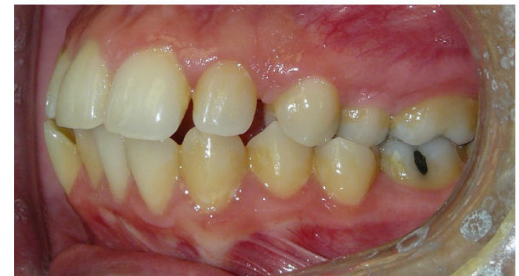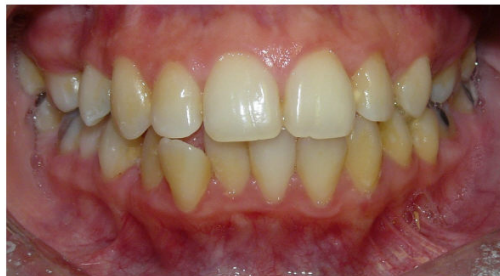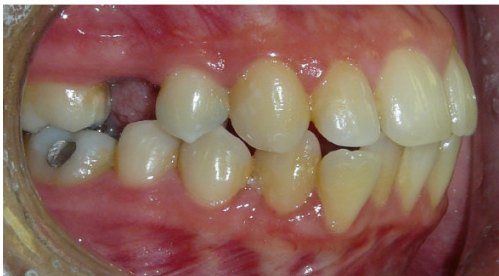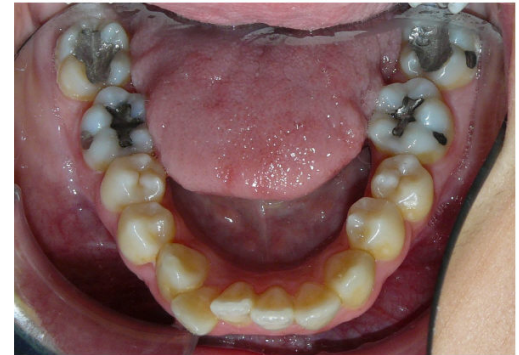Jenifer Shultz

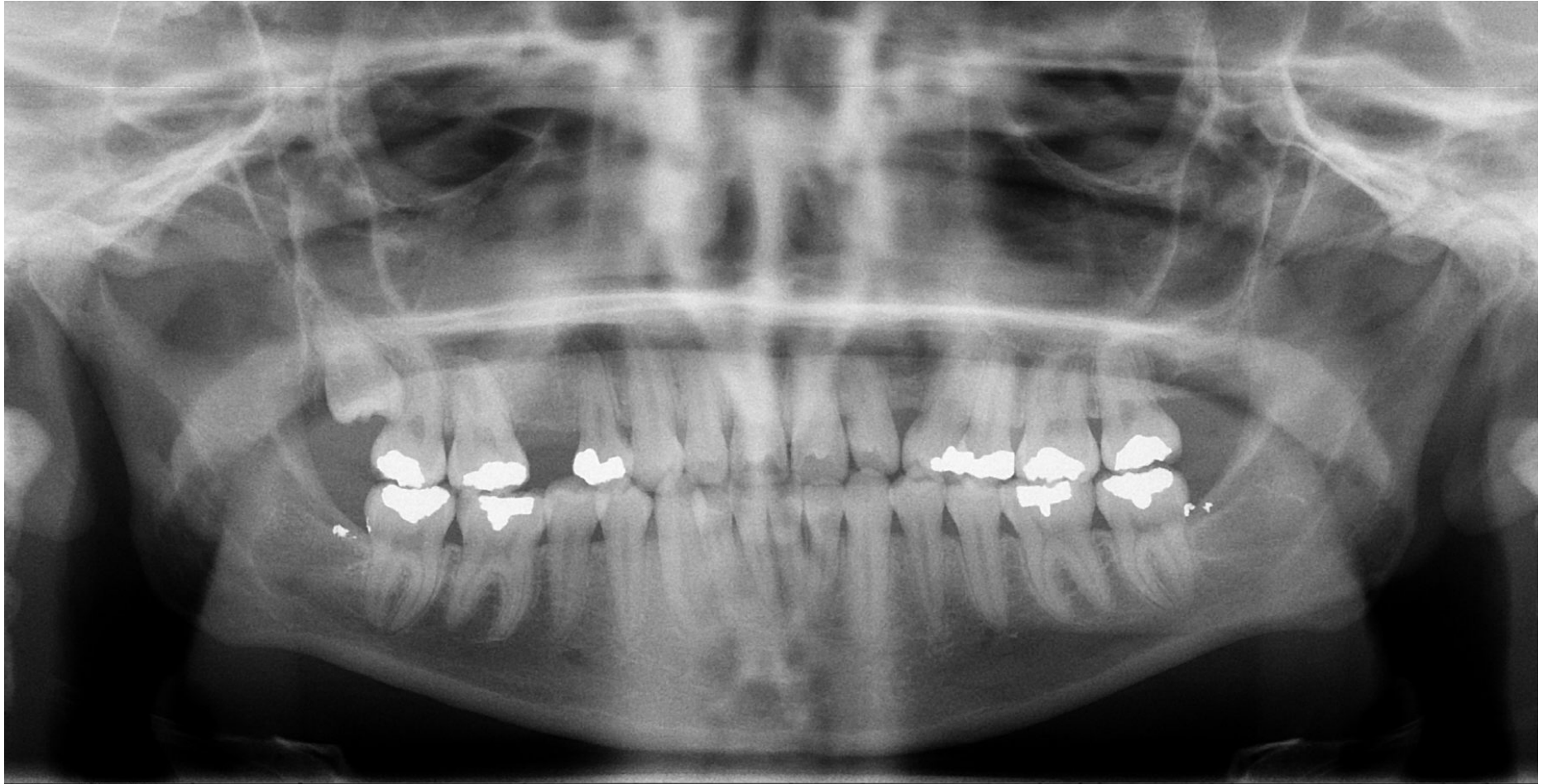
11/3/2008



Initial

20y5m





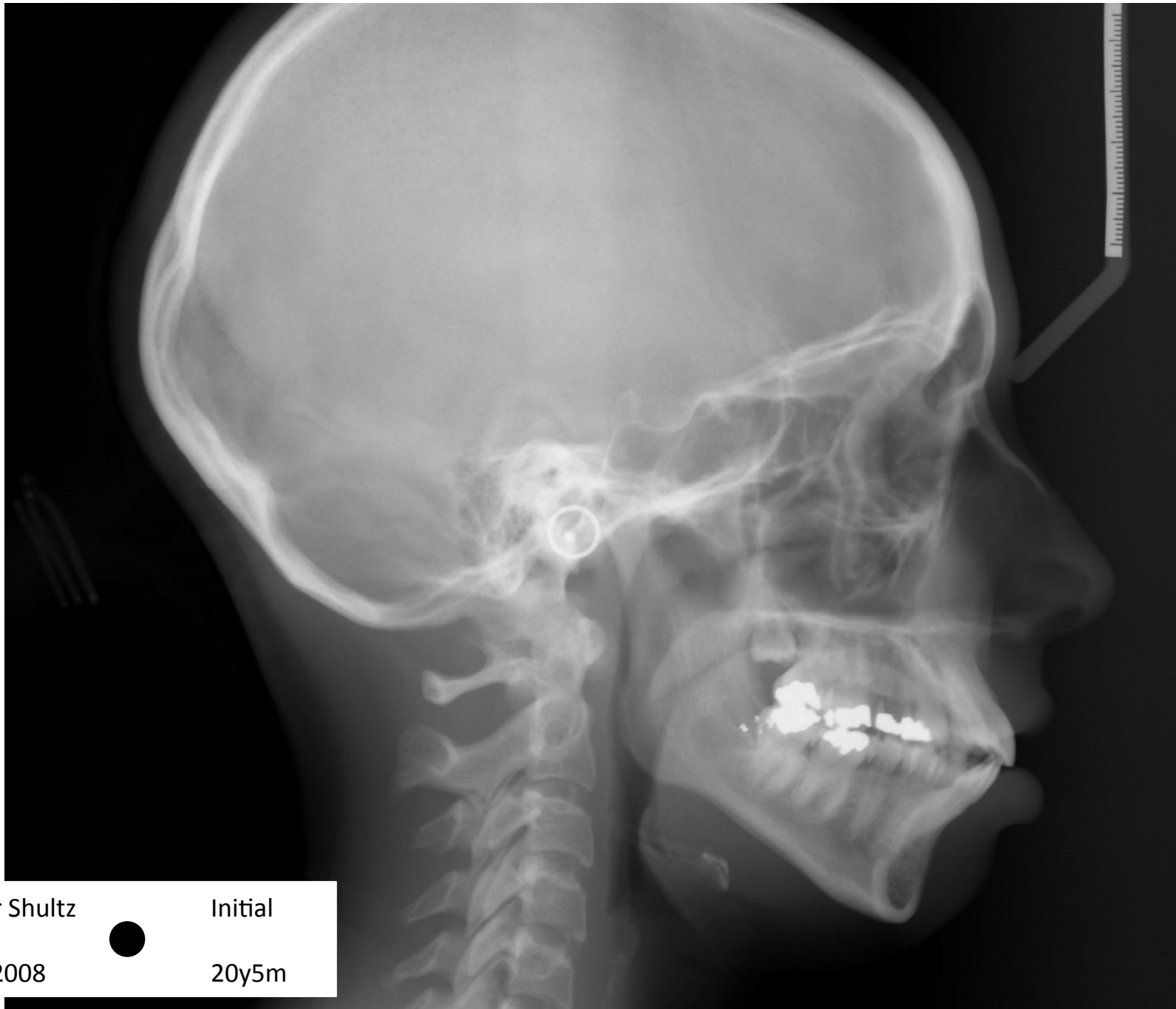
Jenifer Shultz

11/3/2008



Initial

20y5m



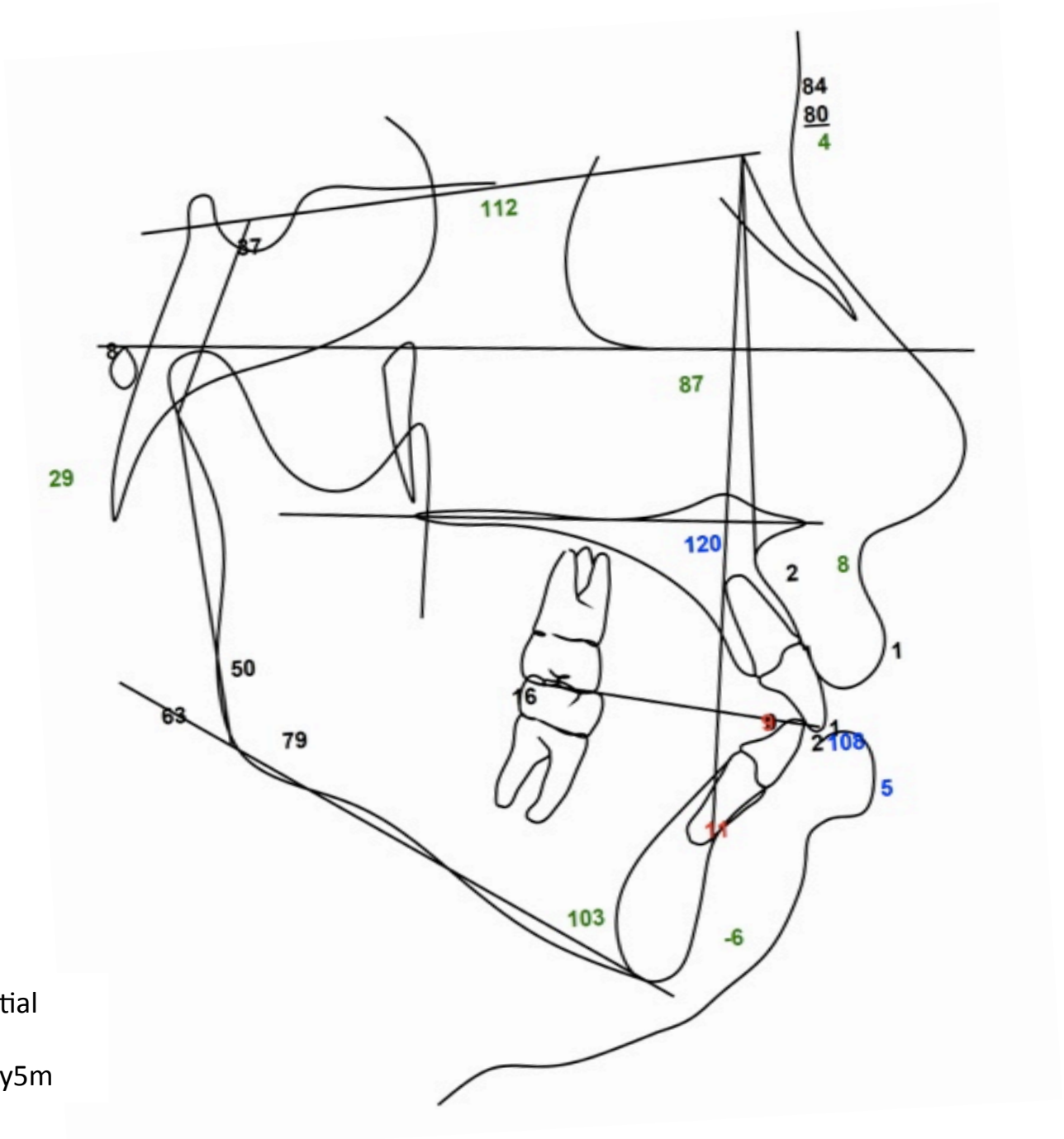
Jenifer Shultz

Initial

11/3/2008



20y5m



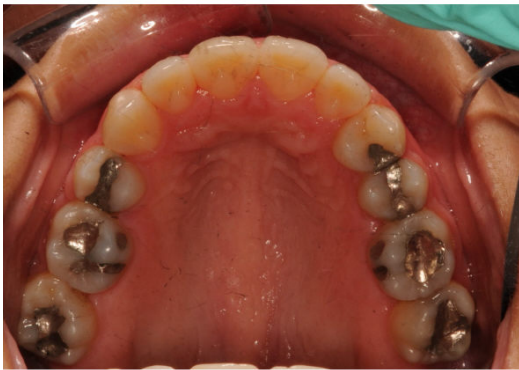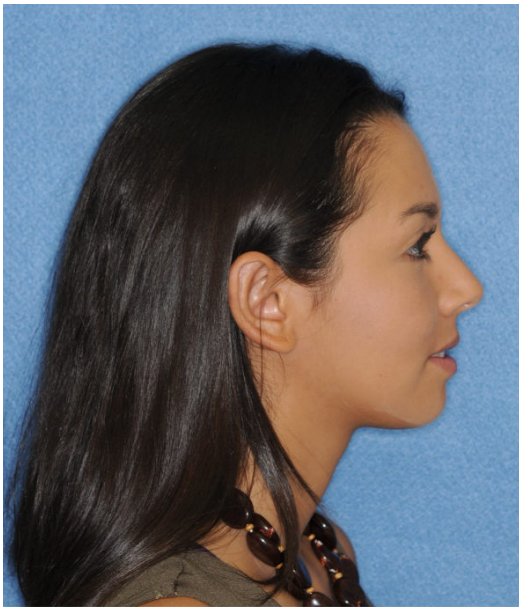Jenifer Shultz

Initial

11/3/2008



20y5m



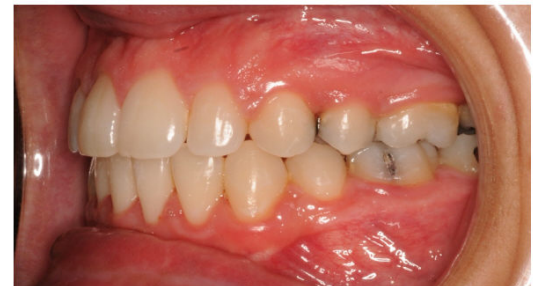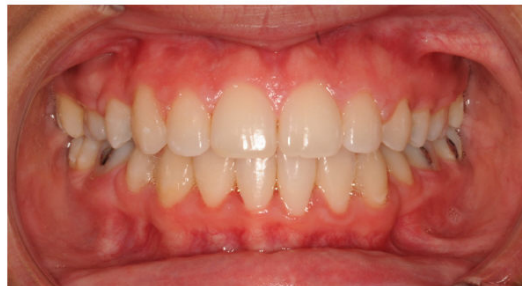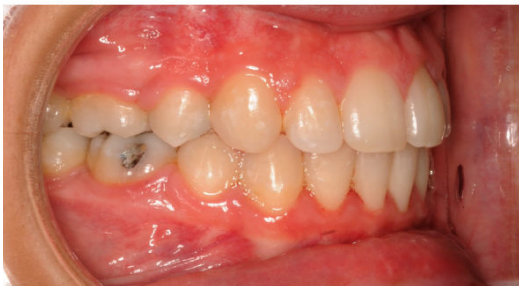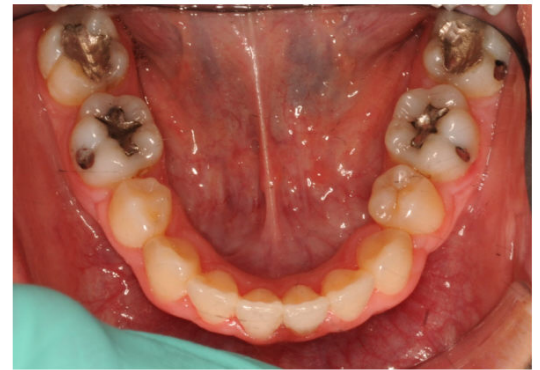Jenifer Shultz

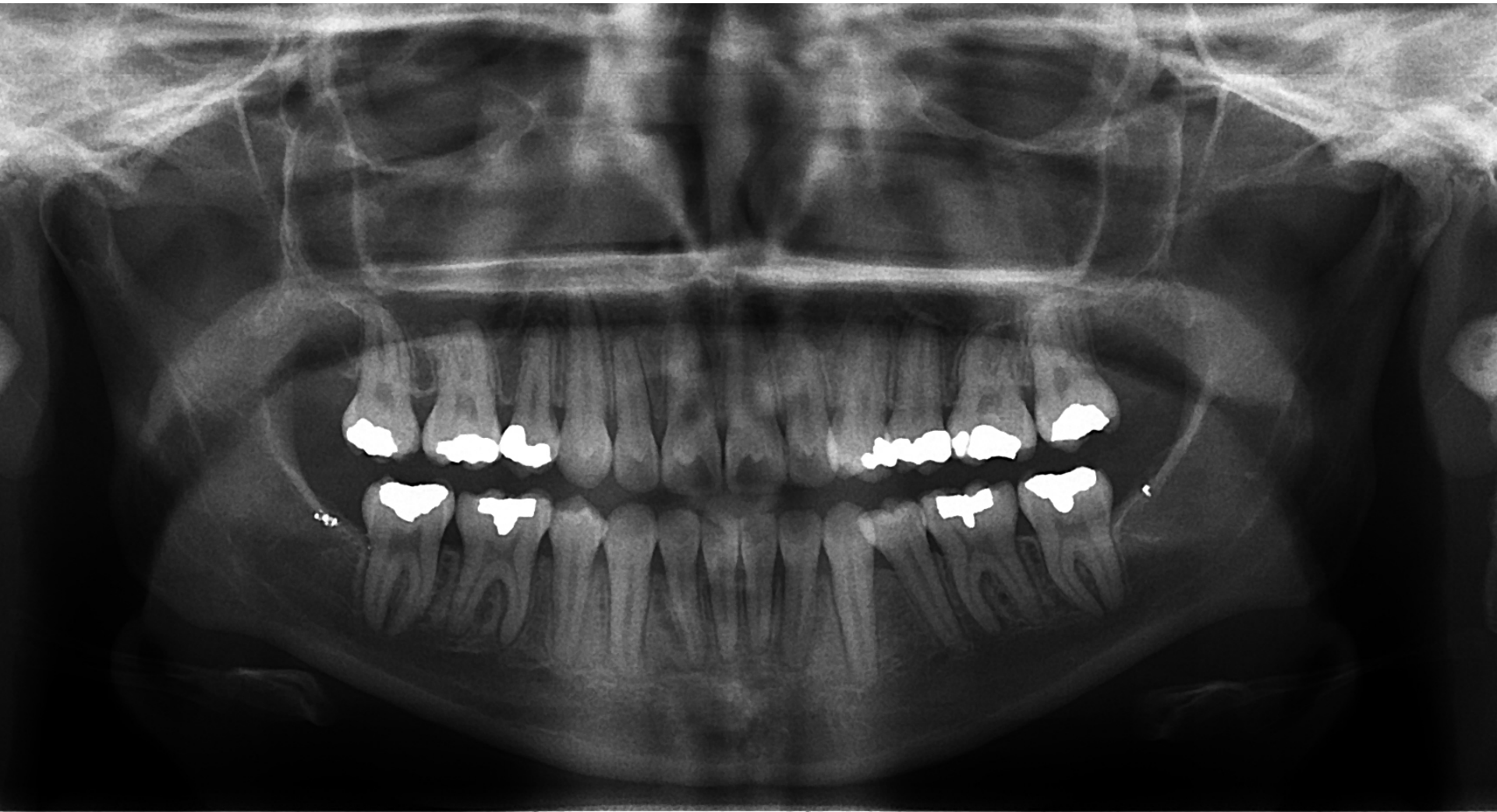
08/13/2010



Final

22y1m





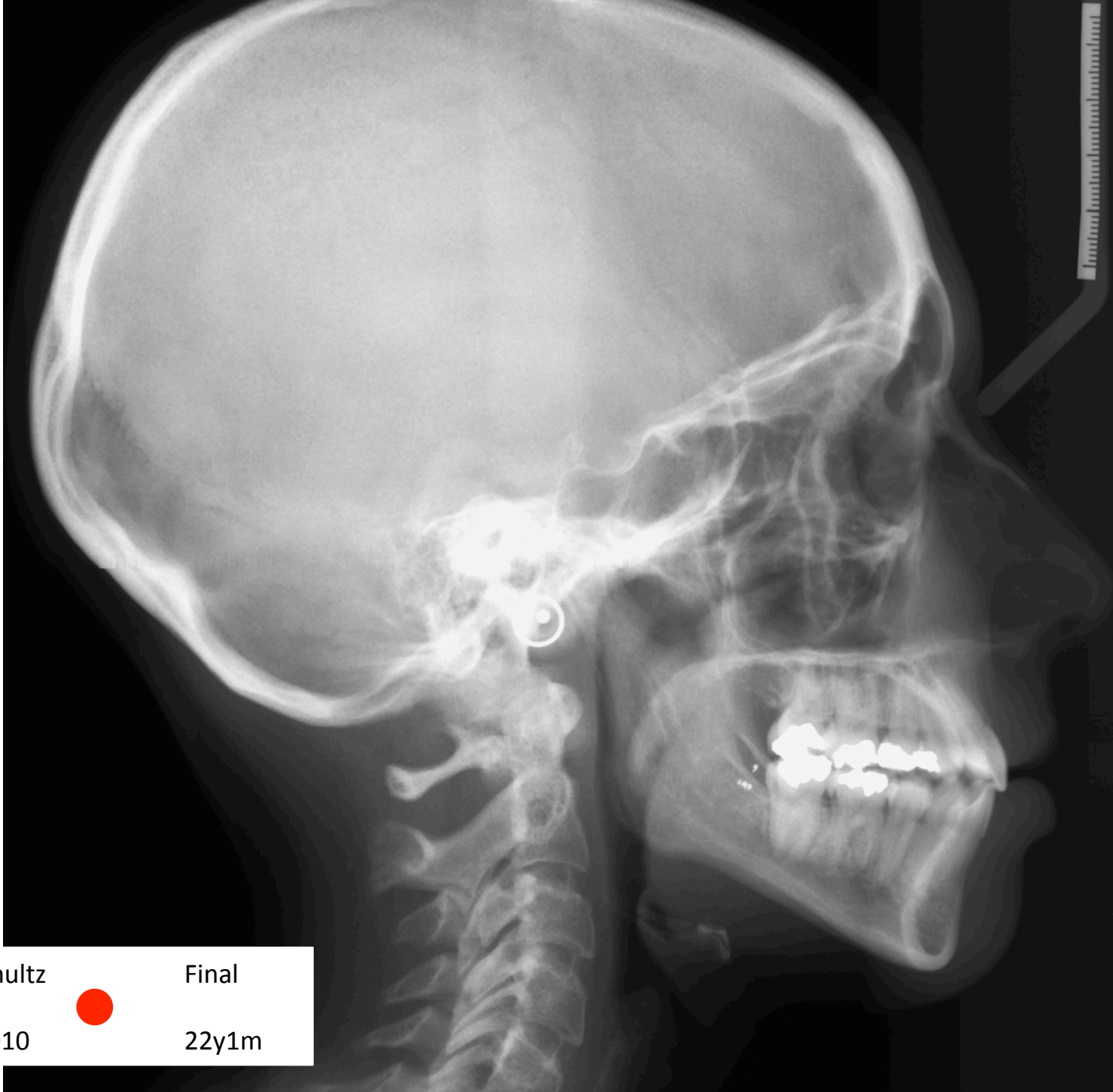
Jenifer Shultz

Final

08/13/2010



22y1m



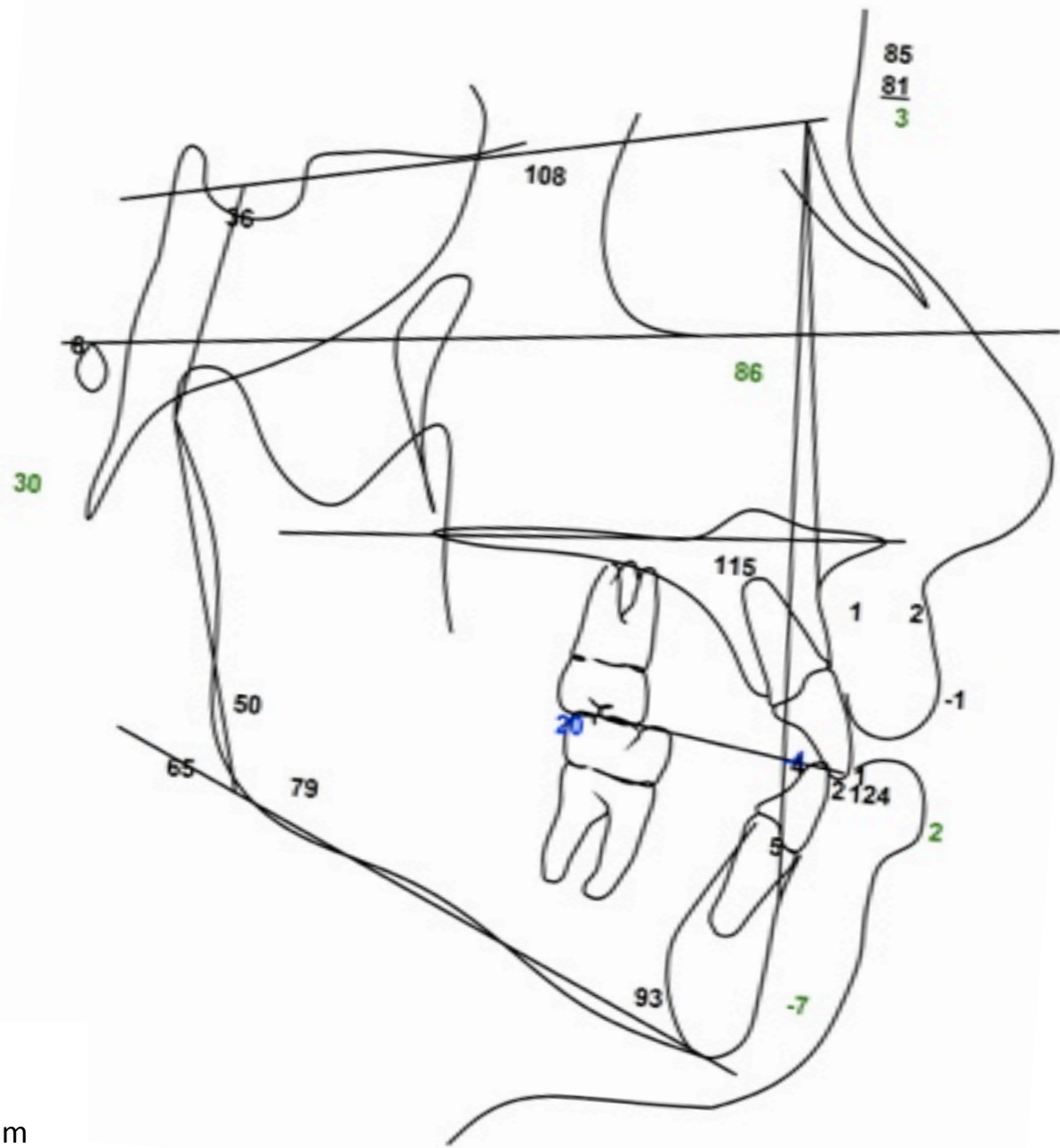
Jenifer Shultz

Final

08/13/2010



22y1m



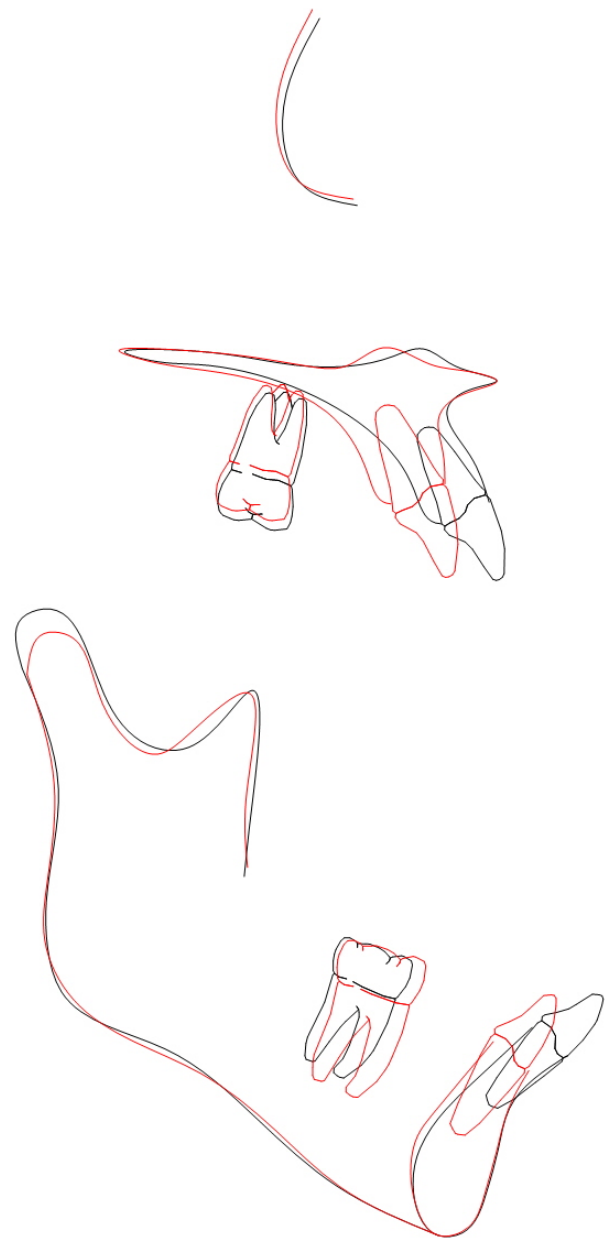
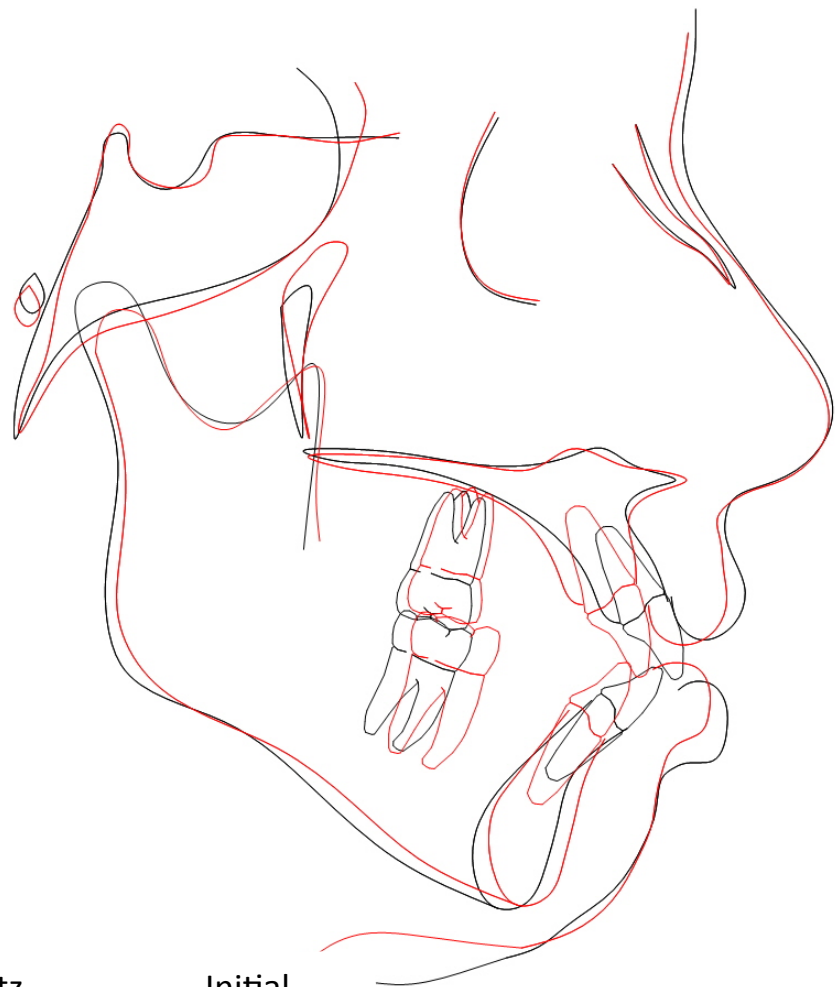
Jenifer Shultz

Final

08/13/2010

22y1m





Jenifer Shultz

11/3/2008

Jenifer Shultz

08/13/2010



Initial

20y5m



Final

22y1m