



Maria Isabel Atique-Rojas

Clear Aligners

San Antonio

January 29-31 2026

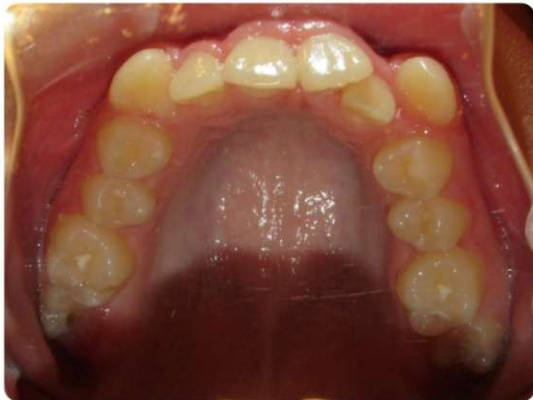
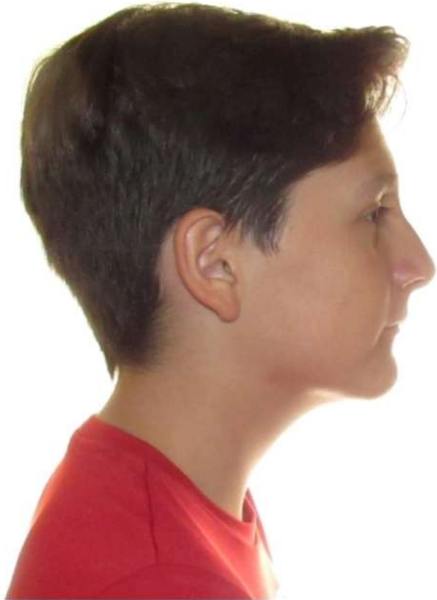
Case Description Summary

1. Bimaxillary retrusion, Class II malocclusion with maxillary and mandibular crowding, ectopic maxillary canines, severely retroclined maxillary incisors and significantly deep bite.
2. Appliances used: Clear aligners (Invisalign)
3. Mechanics used: a combination of maxillary distalization, lingual root torque of maxillary incisors and mandibular forward growth (orthopedic advancement). Class II elastics and precision bite ramps on upper incisors.
4. Other: 2nd opinion ortho consult. Patient had previous ortho consults, one recommended maxillary 1st premolar extractions & another non-extractions with mandibular surgical advancement.

Case Classification, Timeline, and Retention Details

Case	#2
Beginning age	13 years 11 months
Angle Class	Class II
Date Begun	Diagnosis: 07/26/2021 Bonded attachments, delivered aligners 09/15/2021
Date Finished	Removed attachments 07/18/2023
Treatment Time	20 months
Type of Retention	Maxillary and Mandibular Essix Bonded lingual lower 3-3 retainer



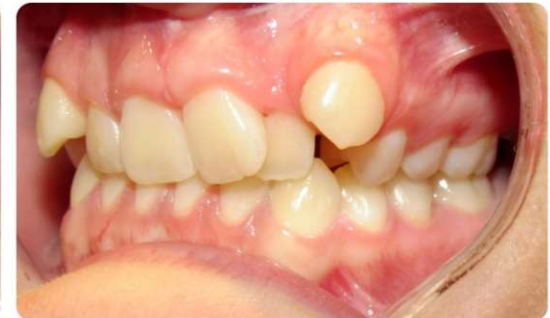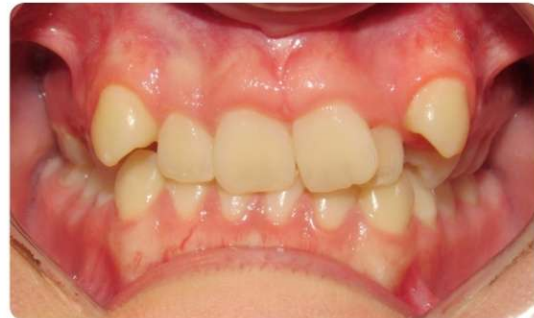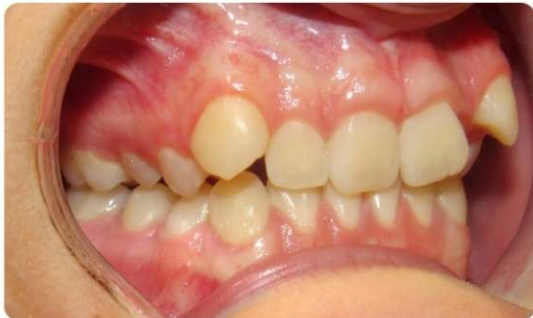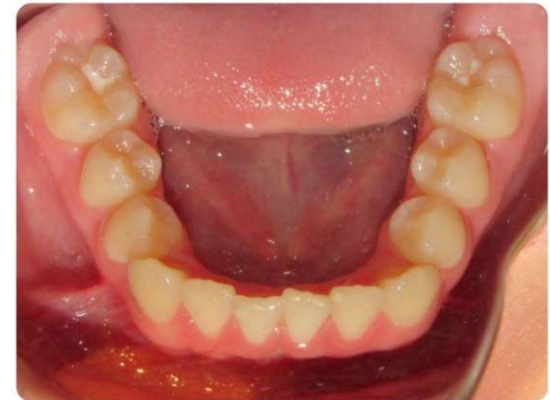DD15515

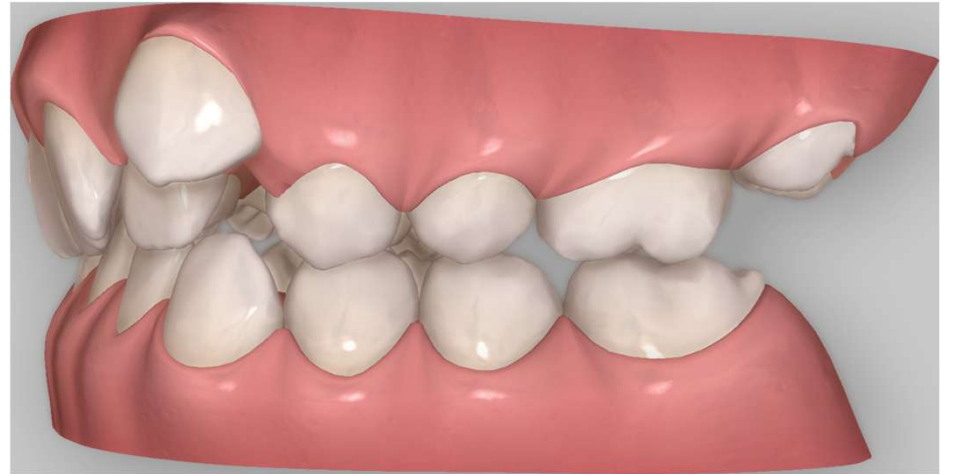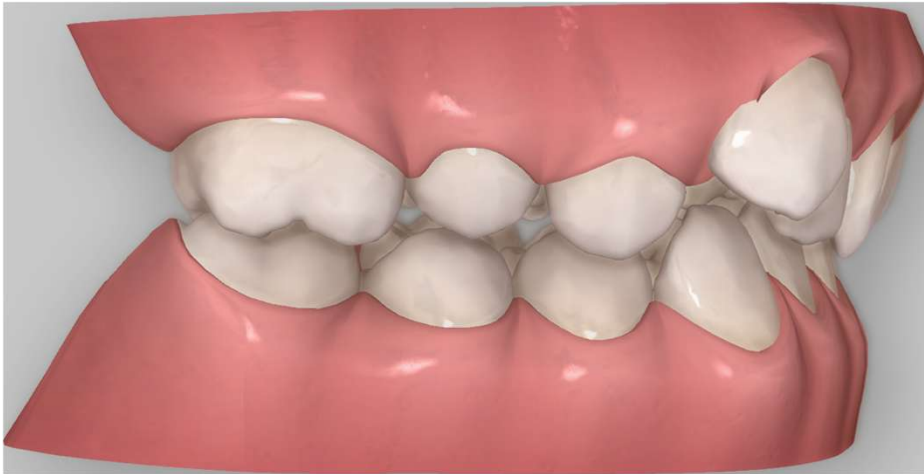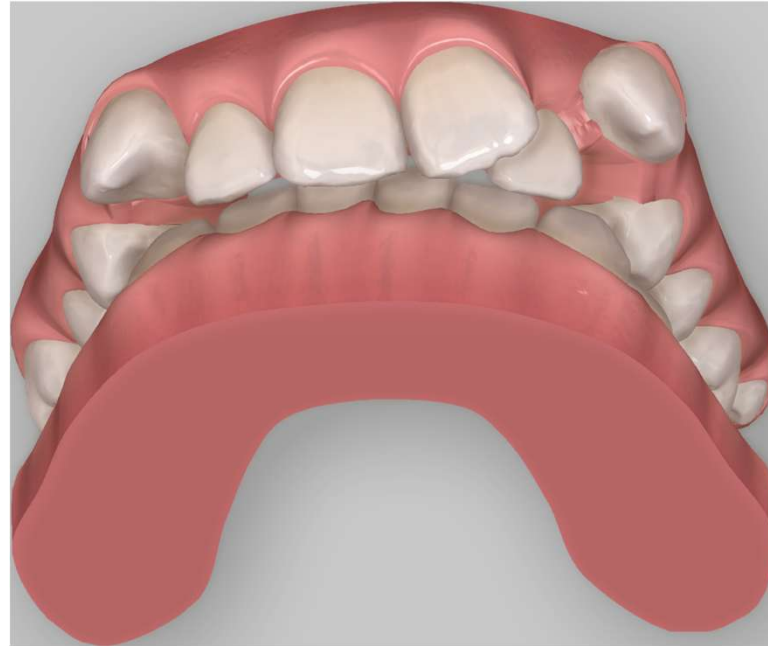
07/26/2021



Initial

13y 11m





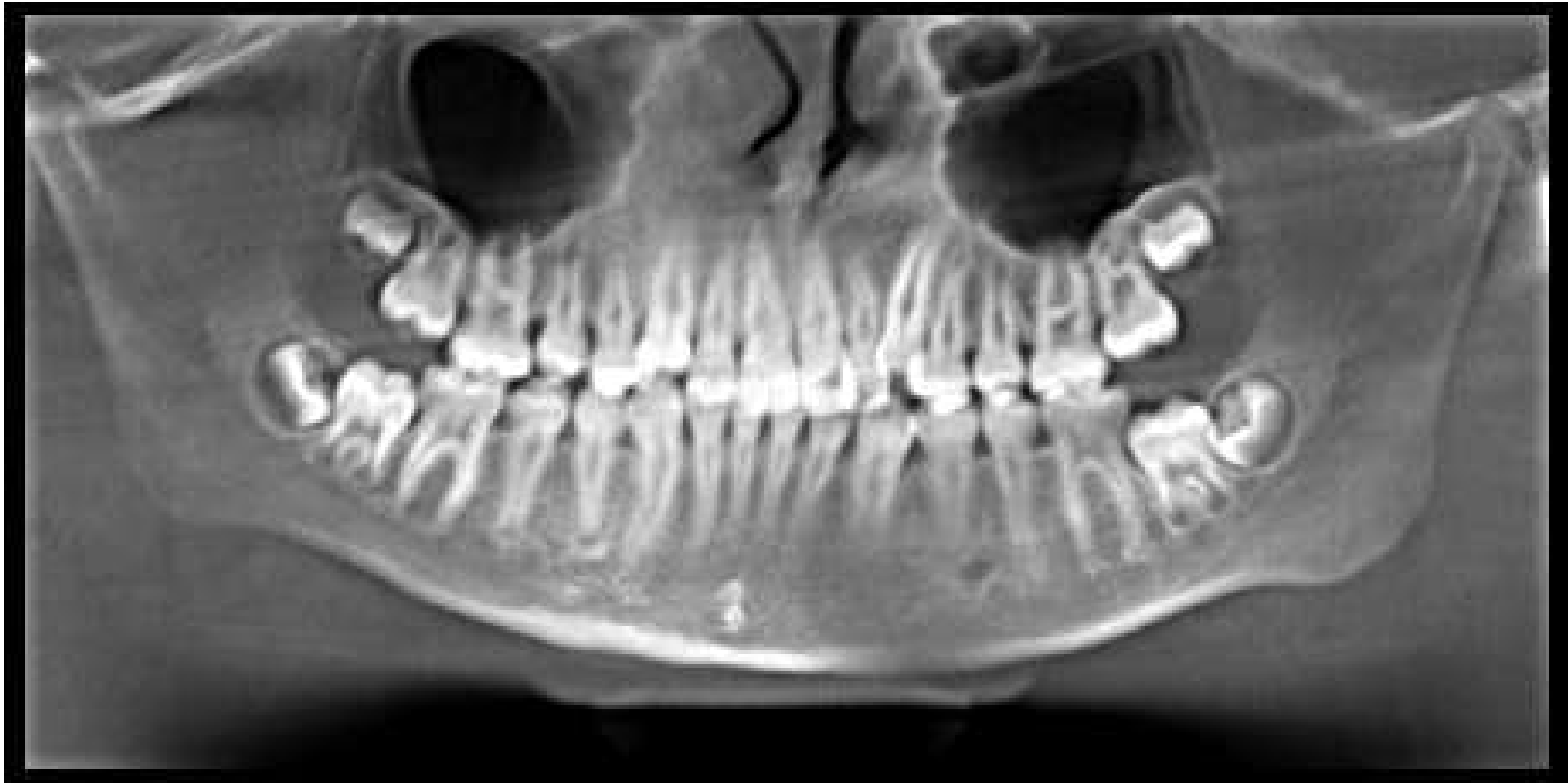DD15515

07/26/2021



Initial

13y 11m



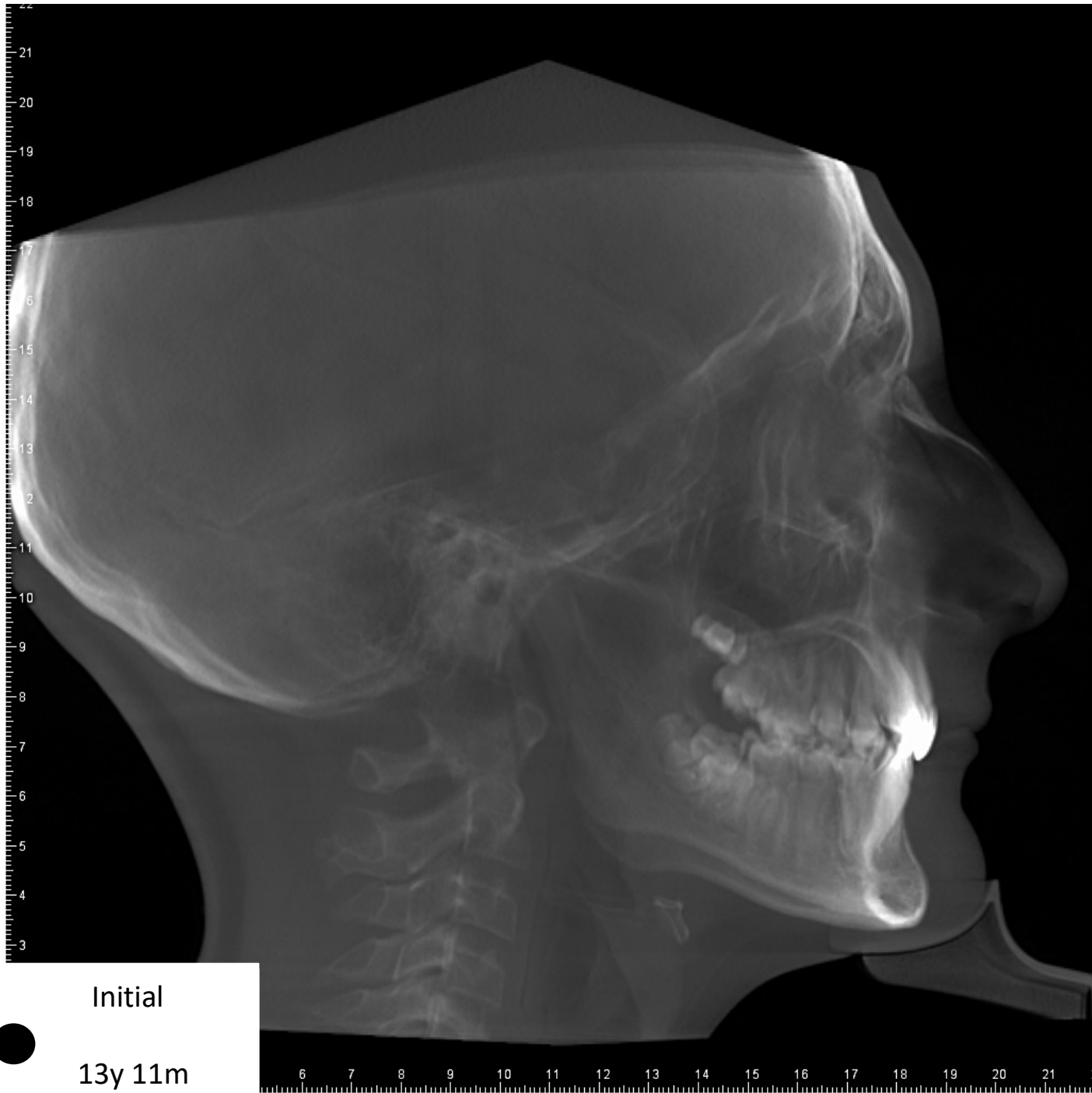
DD15515

Initial

07/26/2021



13y 11m



DD15515

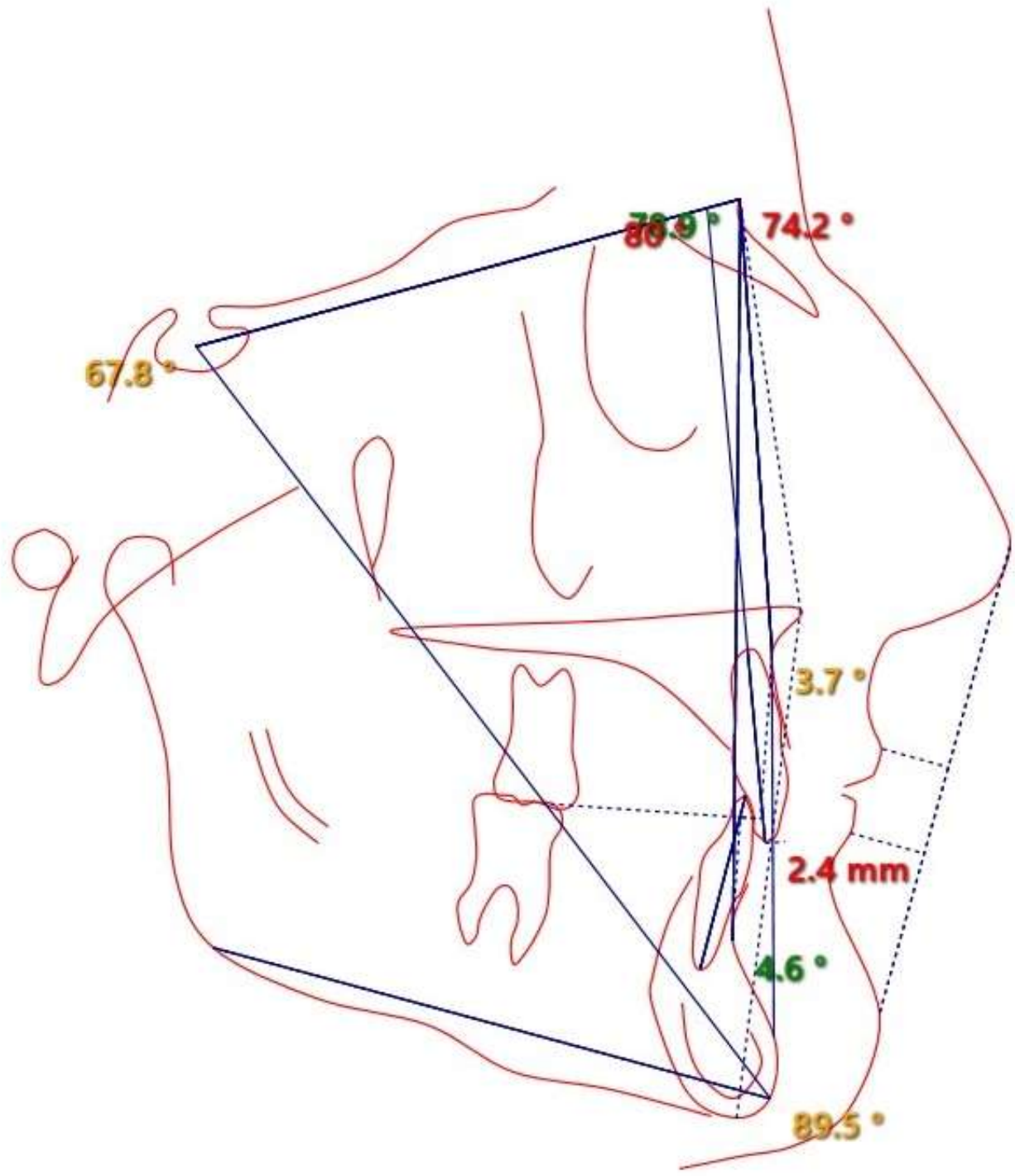
Initial

07/26/2021



13y 11m

6 7 8 9 10 11 12 13 14 15 16 17 18 19 20 21



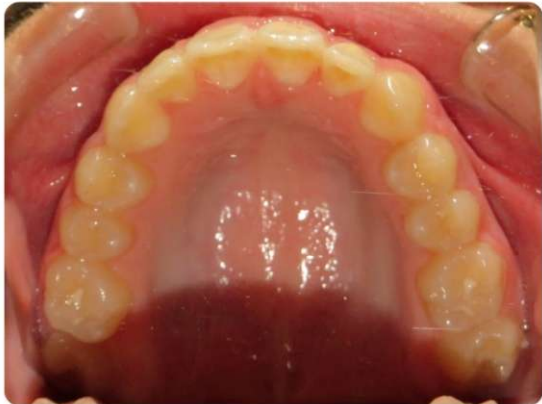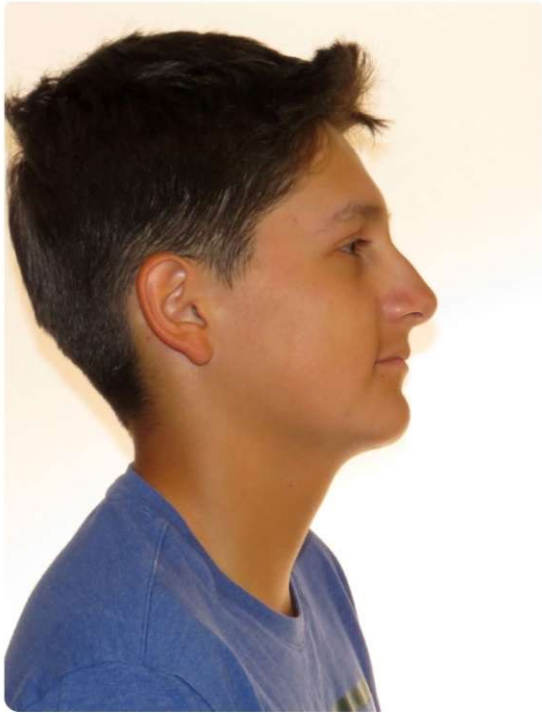DD15515

Initial

07/26/2021

13y 11m





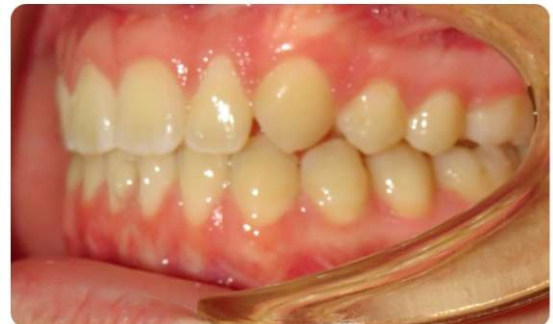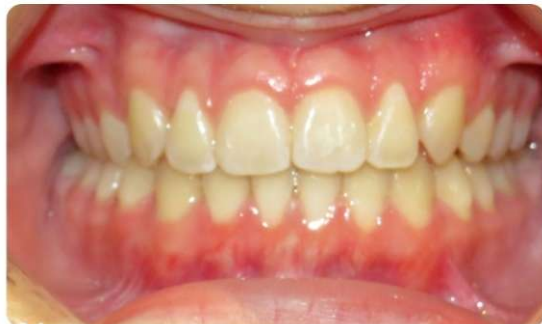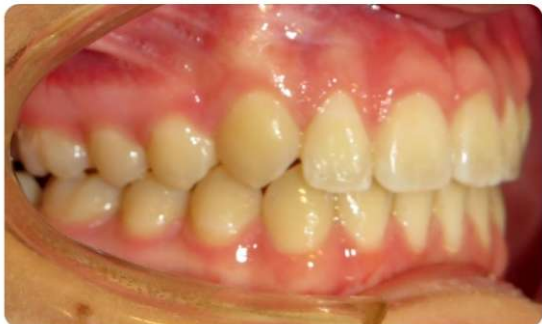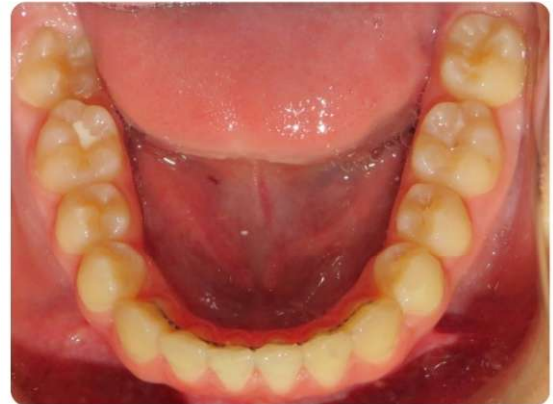DD15515

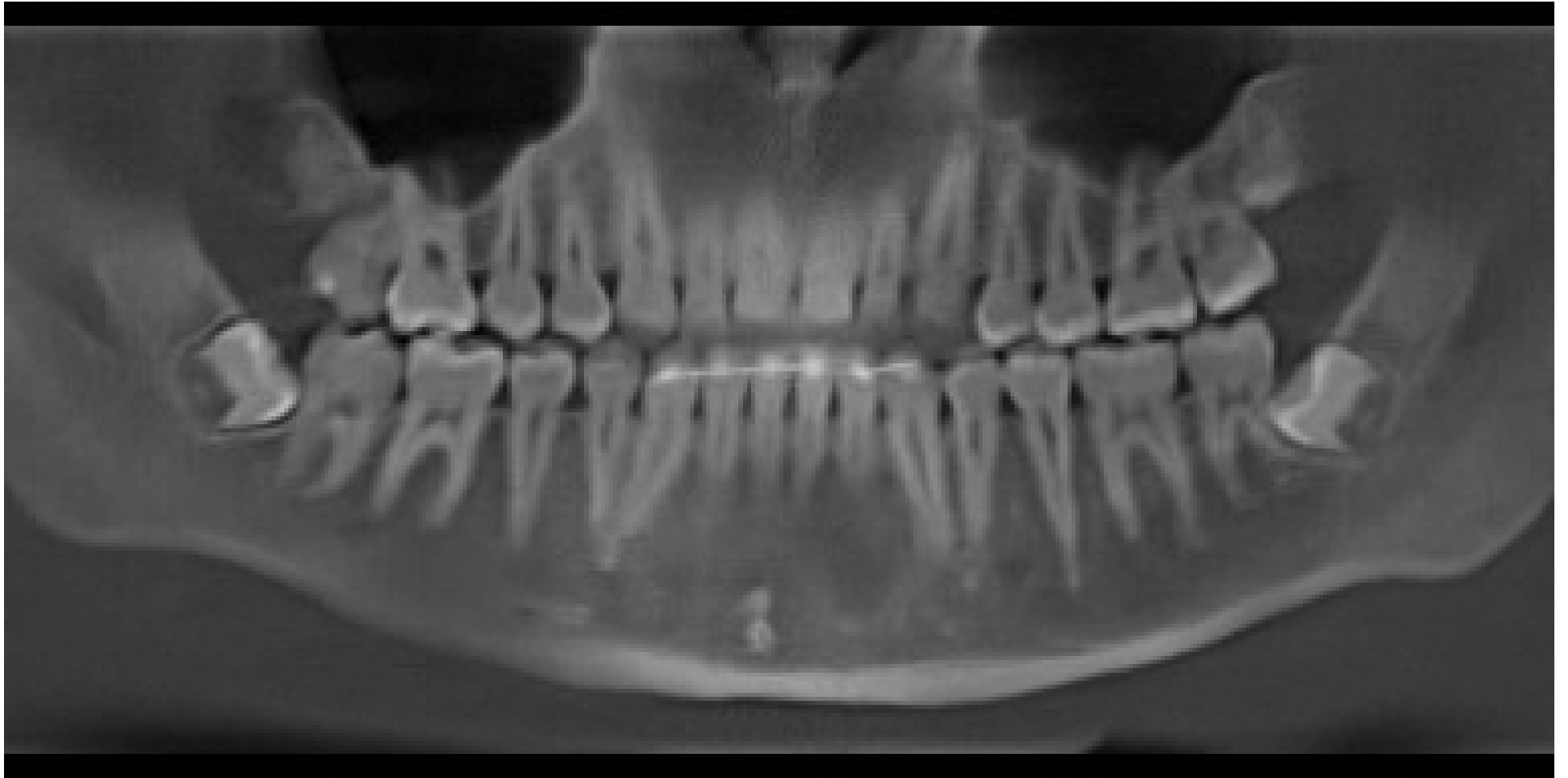
07/18/2023



Final

15y11m





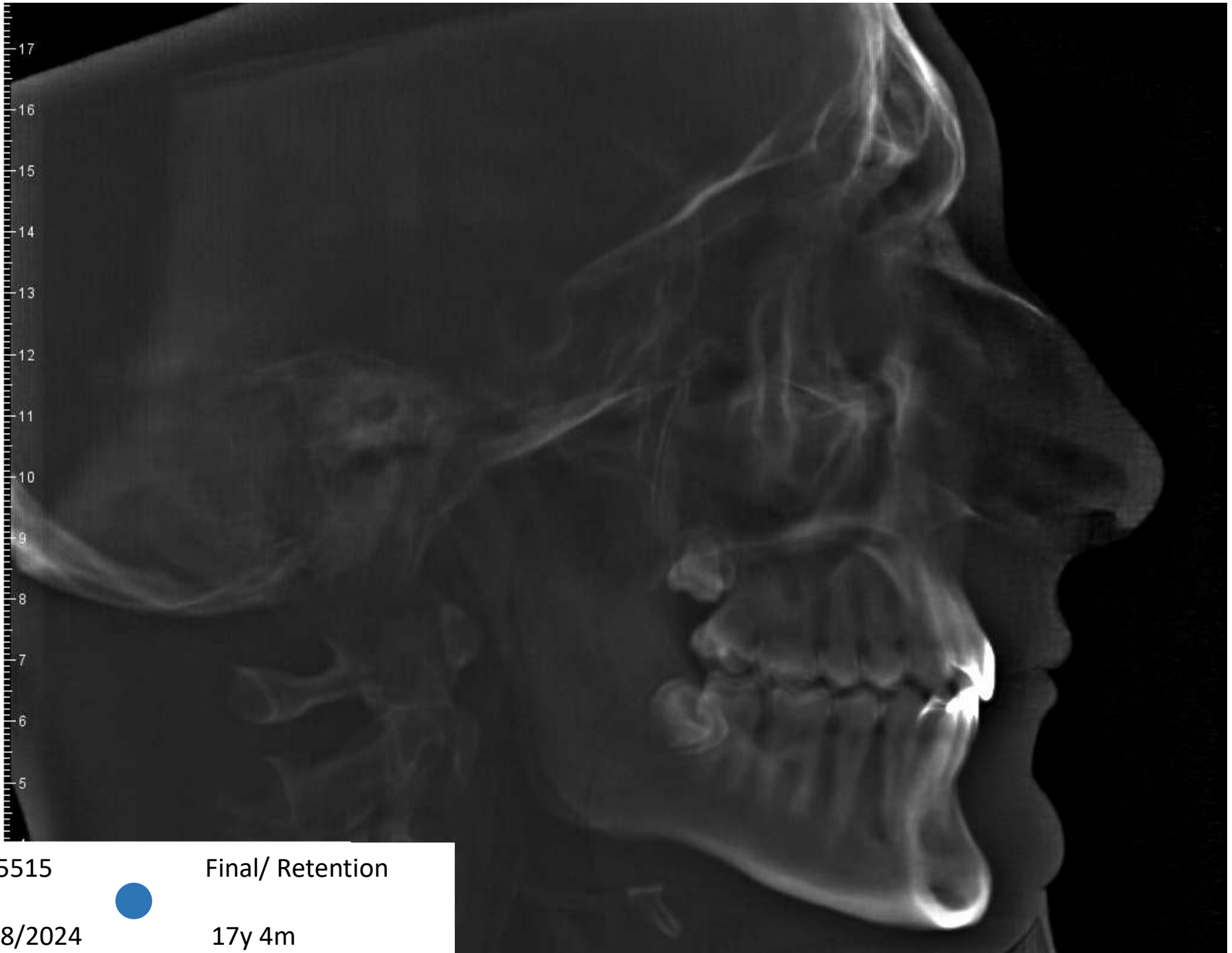DD15515

Final / Retention

12/08/2024



17y 4m



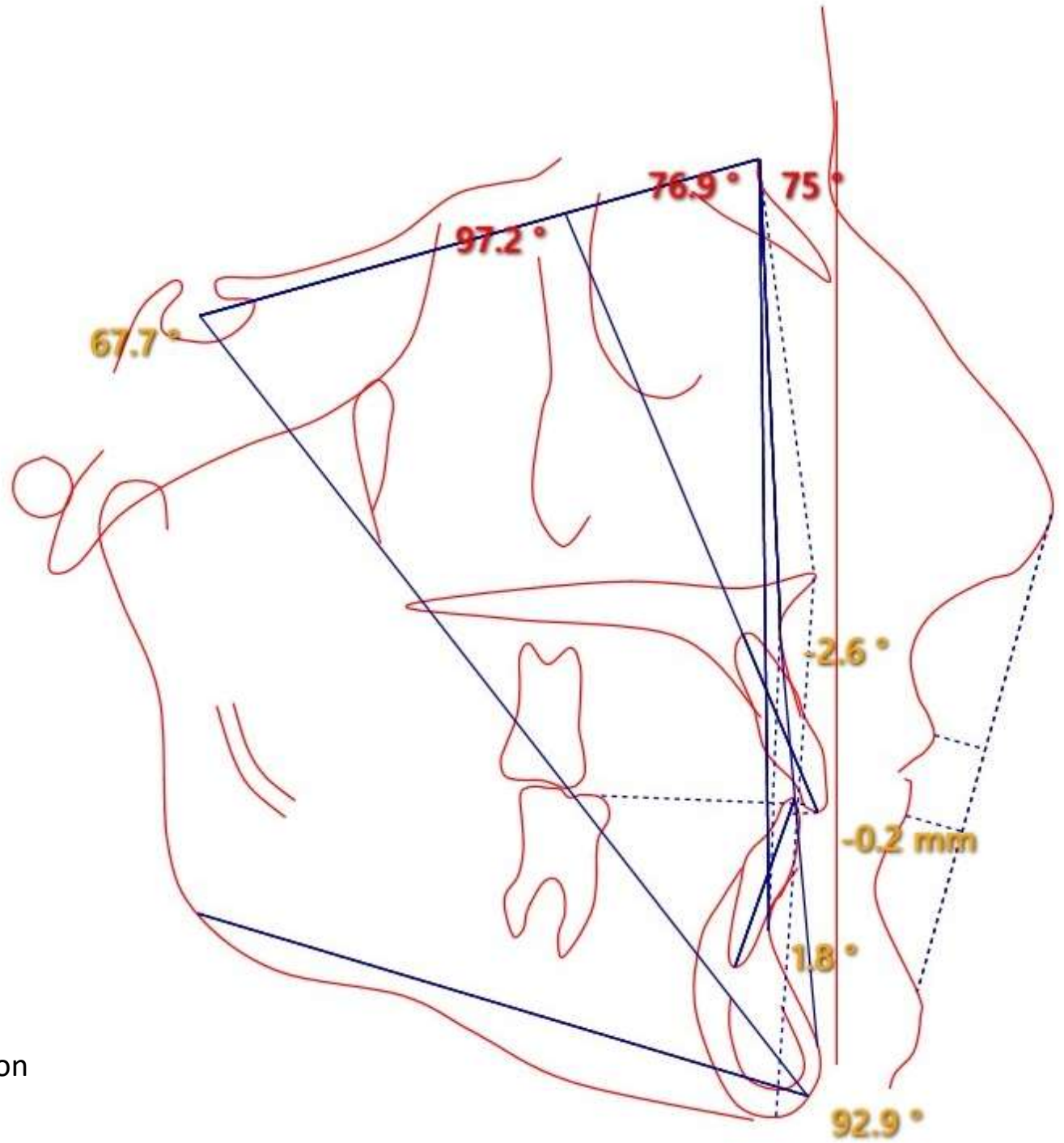
DD15515

12/08/2024



Final/ Retention

17y 4m



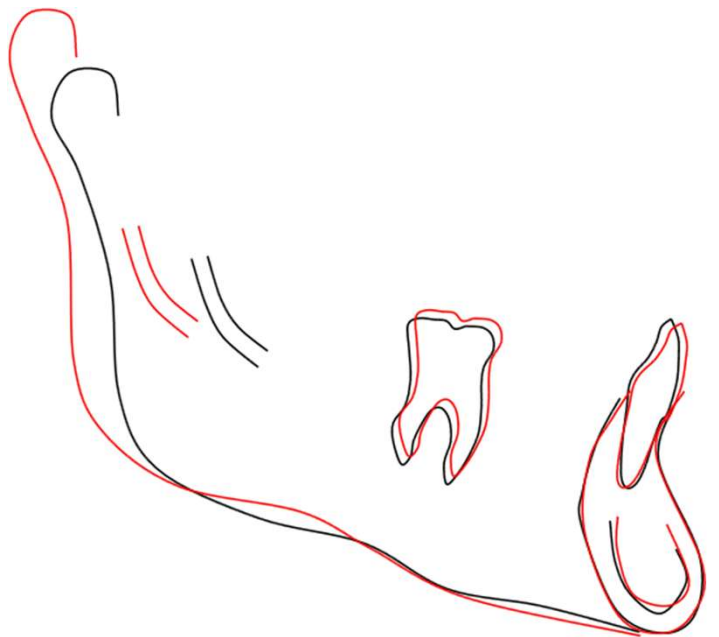
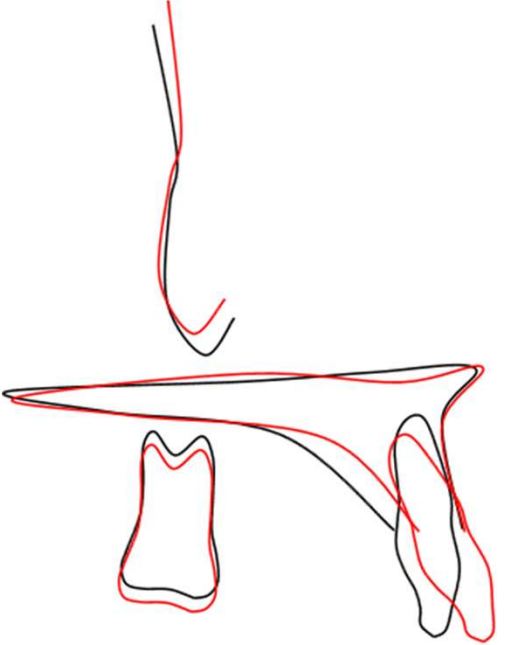
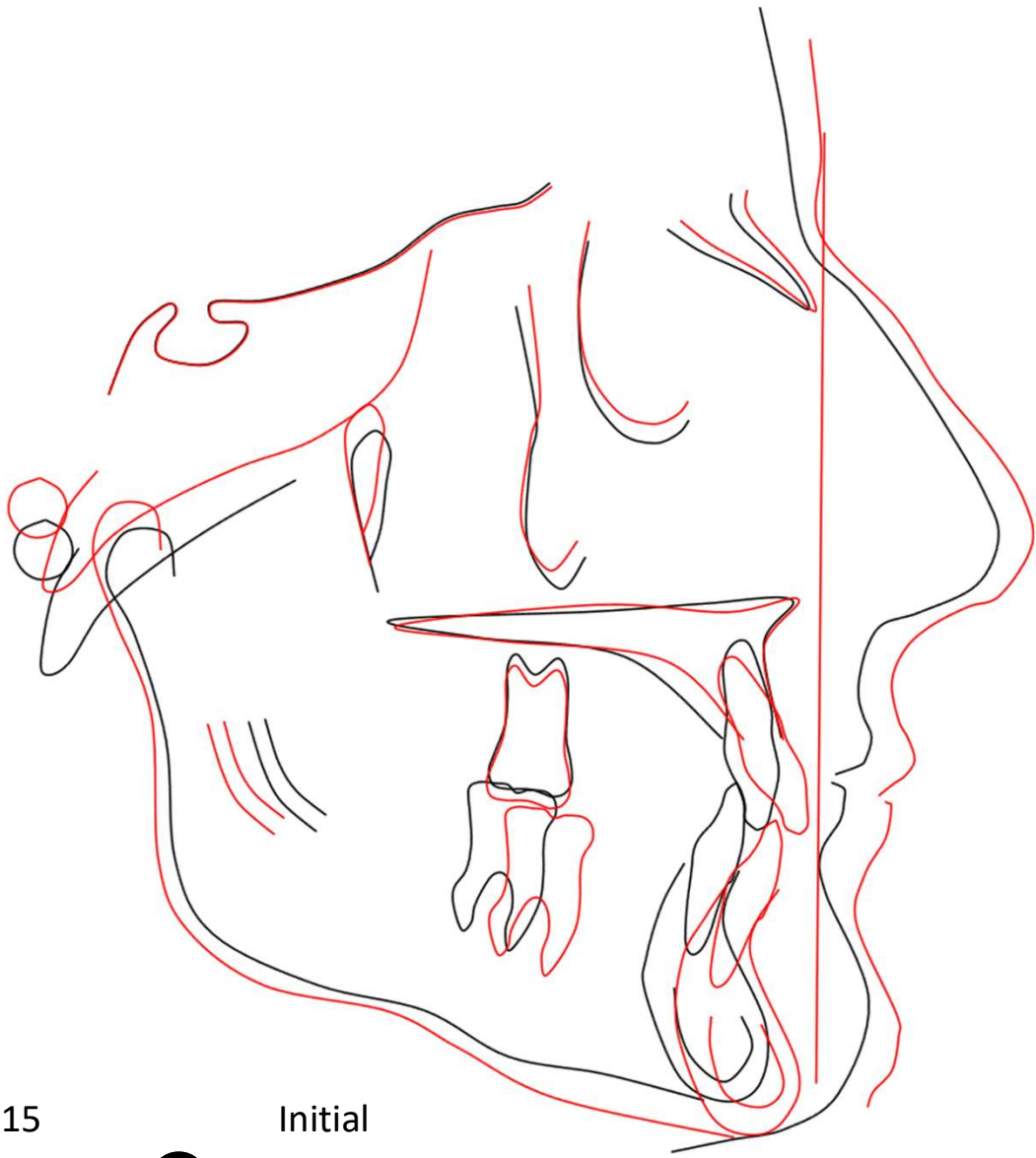
DD15515

12/08/2024



Final/ Retention

17y 4m



DD15515

Initial

07/26/2021



13y 11m

DD15515

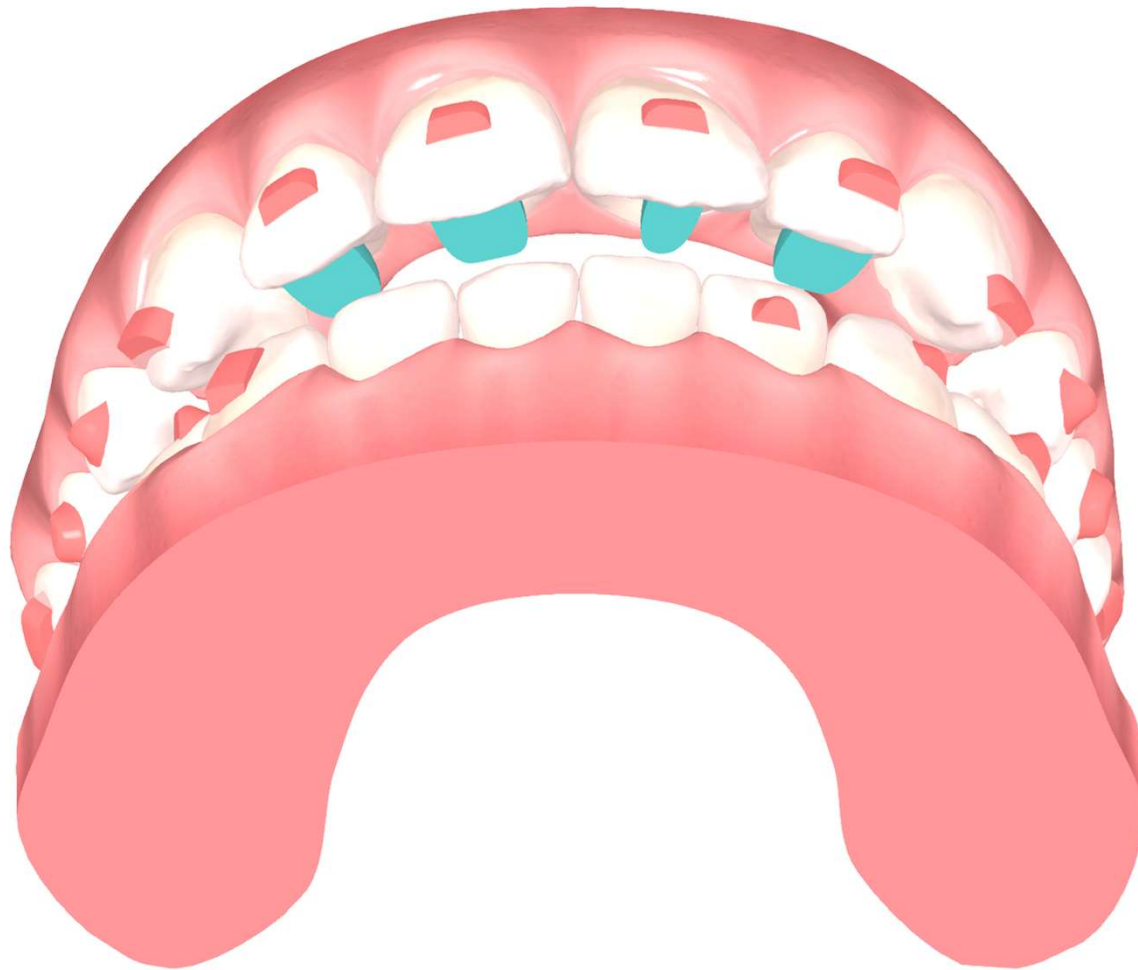
Final/ Retention

12/08/2024

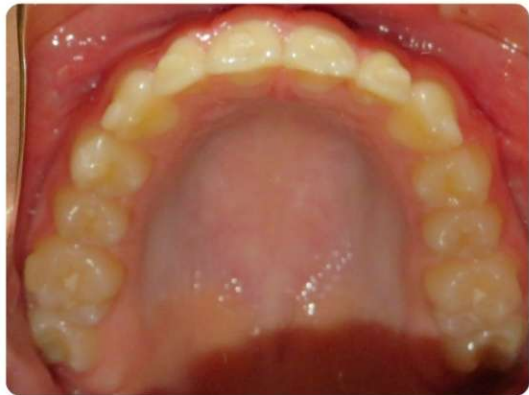

17y 4m

Progress Records



OVERJET 1st ClinCheck, before the bite jump, after applying palatal root torque to upper incisors

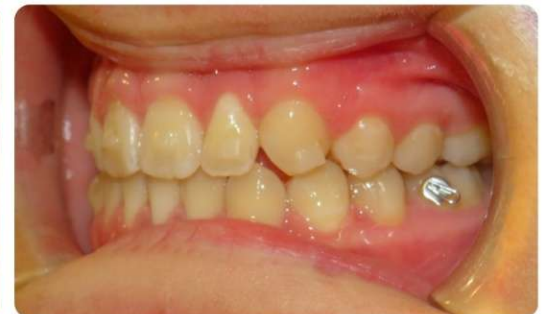
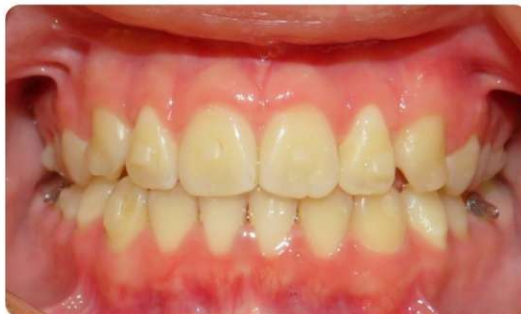
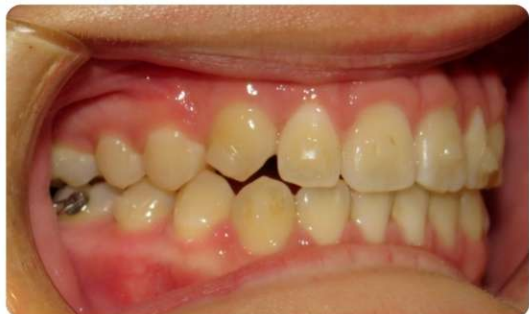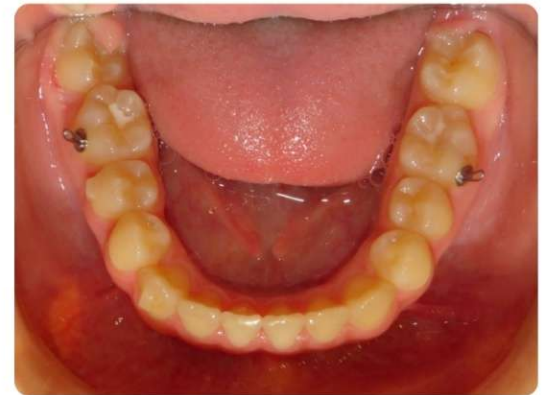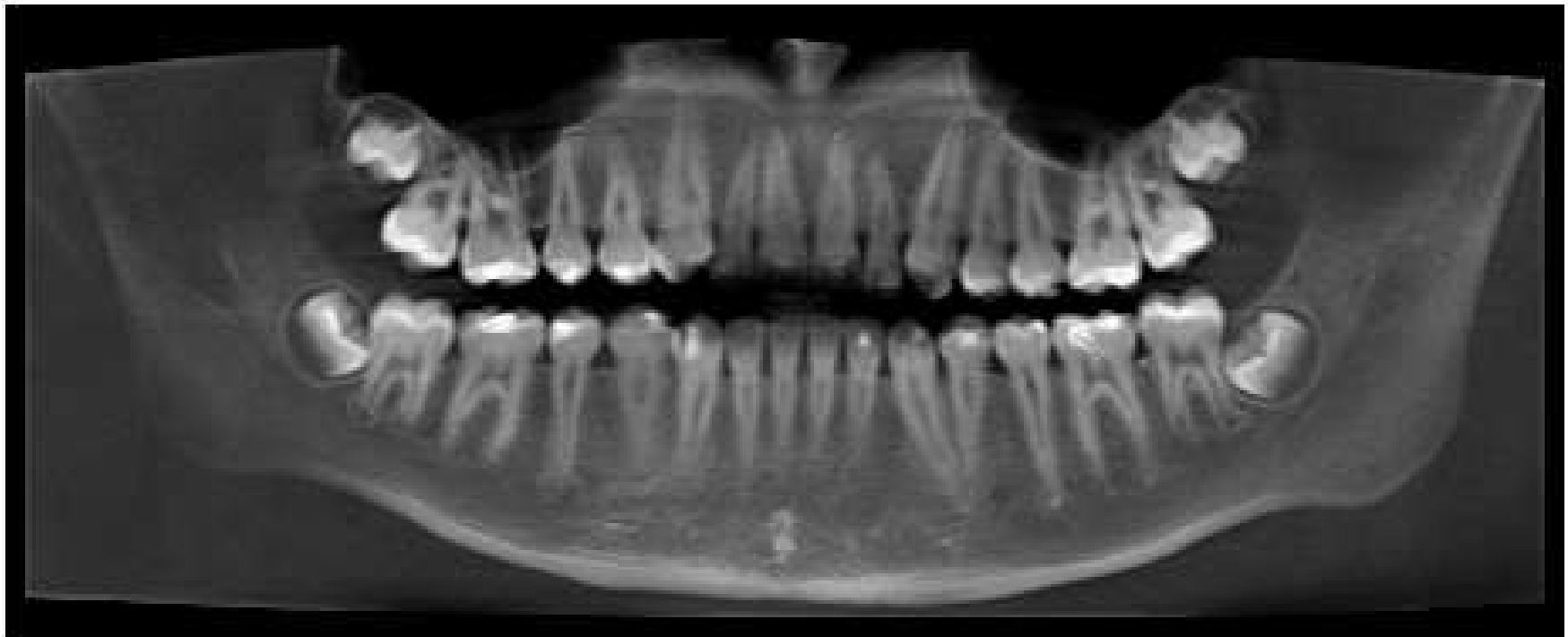
DD1551

Refinement

1/19/2023

15y 5m





DD1551

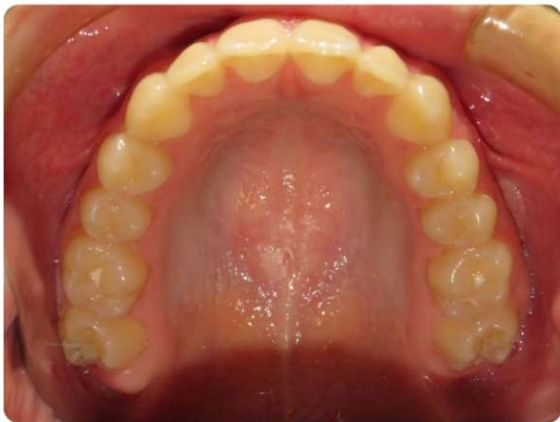
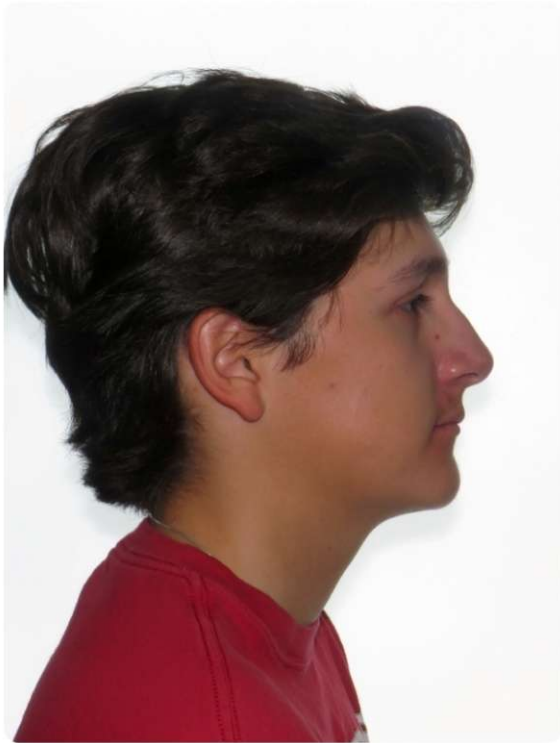Refinement

1/19/2023

15y 5m



Post-treatment



DD15515



18-month
Retention

12/08/2024

17y 4m

