



Cele Oliver

Extraction

San Antonio, Texas

Jan 28-31, 2026



## Case Description Summary

1. MA was seen as a new pedo patient on 7/5/2019. At that appointment I told her parents she had ectopic and impacted U 3s, significant root resorption U 2-2, an anterior open bite and anterior crossbite. I recommended to have a phase I consult and extraction of U Cs and D s immediately. She no-showed both her extraction and consult appointments.

On 1/15/ 2020, she presented for her 6 month recare, and I forced a same day consult. I recommended extractions of U Cs and Ds and an RPE with a tongue crib and anteriorly directed hooks (to guide U3s eruption. She was informed she will eventually lose U 1s but we will attempt to save U 2s. On 2/19/20 she had primary extractions done but did not start ortho due to financial reasons.

12/21/20 she presented with trauma from running into another student at school. She had class III mobility U 2-2, fluctuant alveolus and laceration of labial mucosa and labial hematoma. Diagnosis: extrusive luxation #s 7, 8, 9 and 10 (all displaced out of alveolus) and a likely alveolar fracture. Treatment: sutures and 014N passive flexible splint 4 weeks minimum. When placing the splint, I seated displaced anterior teeth in the alveolus and used finger pressure to move teeth out of traumatic occlusion and placed turbos so there was no contact on anterior teeth. Emphasized oral hygiene, mouthguard wear and soft diet. Reiterated need to avoid contact with anterior teeth. At this emergency I found that she had started orthodontics elsewhere due to financial reasons and mom states they haven't done anything since RPE was delivered 5 months prior and she thinks phase I must be over. Discussed case with treating orthodontist, who says he was planning on placing fixed appliances U 2-2 at next visit. Advised him against orthodontic tooth movement U 2-2 following trauma.

1/4/21, patient dropped her Nintendo switch on U2-2 and now she has pain and returned mobility. Mom is finally scared she will lose her front teeth and wants to change orthodontists due to treating office not being responsive to emergencies and not being more aggressive.

2/5/21, updated records and I referred to perio for a CBCT, evaluate U incisors and to consult for expose and bond U 3s

2/13/21 Pt sees perio who deems prognosis for #s 7, 8, 9 and 10 hopeless. Discussed new treatment plan: Extract U 2s and expose and bond U3s. Will use TPA with hooks hooks palatal to U L2 and centered in arch near U R2 to direct U 3s into arch. Will section and leave splint U 1-1 and bypass U 1s through entirety of treatment to maintain what little root remains until ready for implants. Canine substitution for laterals on upper arch, extraction L 5s due to short roots and impacted L 7s. Hopeless U1s will be maintained and serve esthetic function, as well as maintain gingival architecture for better restorations in the future. Can not maintain U 2s in the same manner, as U L2 had lost all bony support and U R2 would be sacrificed in eruptive pathway of U R3. After growth is complete, patient will require implants U 1s and will benefit from veneers on lateralized canines at that time. Fluoride varnish applications every 3 mo due to poor hygiene and high caries risk.

At the end of February 2021, MA's father passed away from COVID. Her mom is a working mother of 5. Appointments were frequently broken and she would go up to 7 months at a time without being seen.

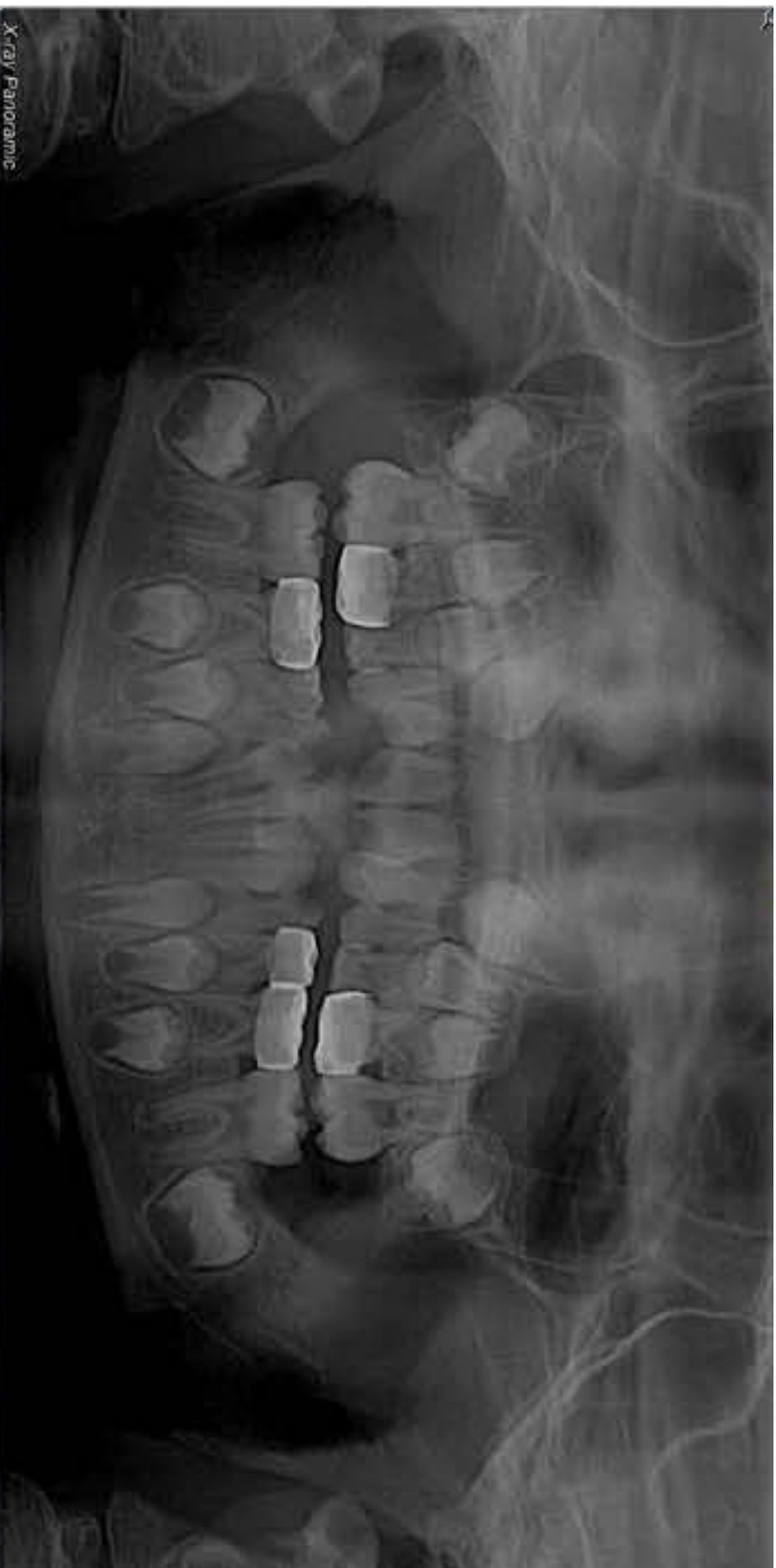2. Appliances Used: TPA, 018 slot Speed appliances, Roth Rx Braces, 014Niti splint U 1-1

3. Mechanics Used: sectional archwires initially to align U3s without taxing U 1s, 3/16 ML elastics U 6s to L 2s on SS A/w that had stopout U 1s (not engaged) for class III anchorage. U 1s never bonded



### **Case Classification, Timeline, and Retention Details**

Beginning age	9 Years, 8 Months
Angle Class	Class I
Date Begun	2/5/2021
Date Finished	9/27/2025
Treatment Time	55 months
Type of Retention	Splinted U3-3 and U Essix Bonded L3-3 and L Essix



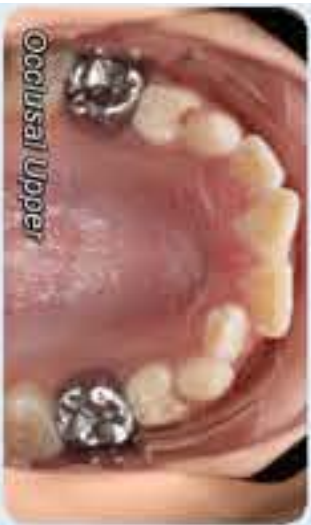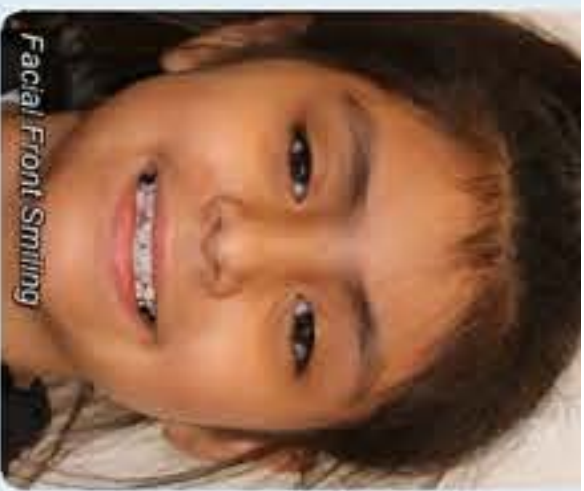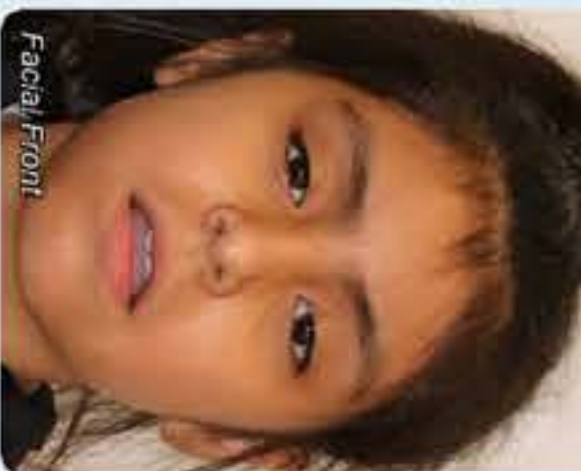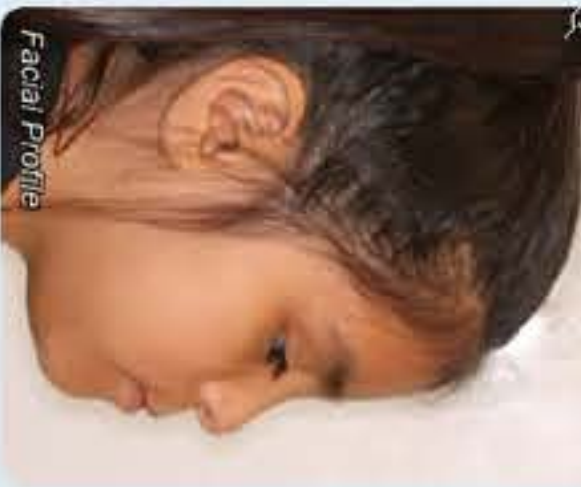MA

Initial

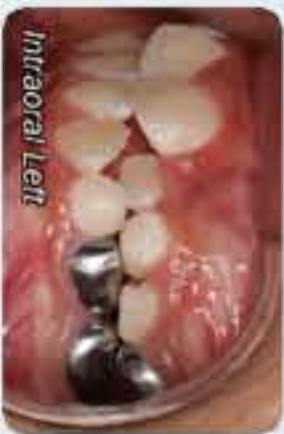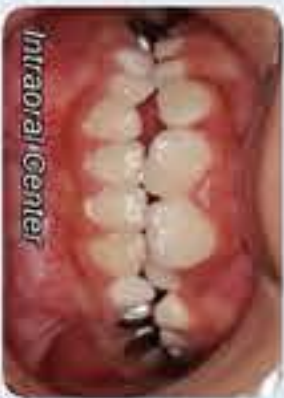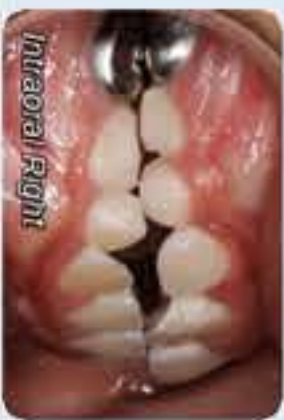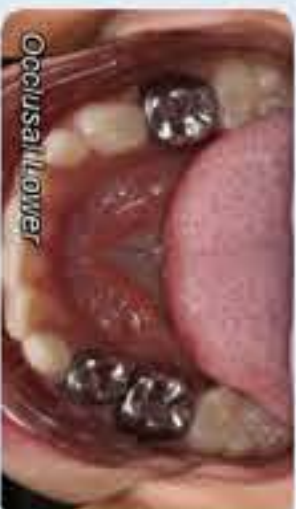6/22/2019

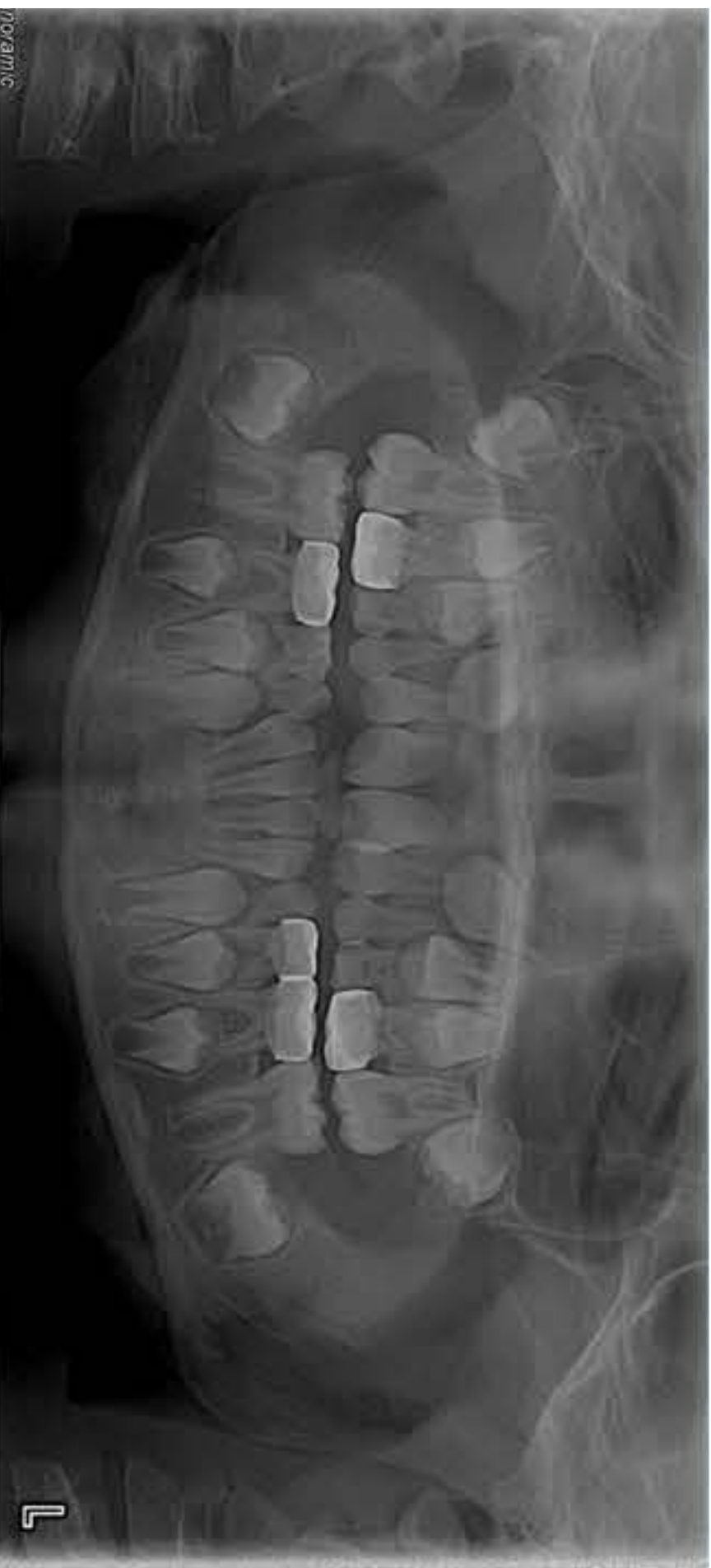8y 0m

Pano from initial pedo exam. I recommended extraction of U Cs and Ds and RPE. Patient no-showed extractions and consult appointments.



MA Initial  
1/15/2020 8y 7m





MA

Initial

1/15/2020

8y 6m

At recare, I forced a consult and noted increased root resorption and U 3s impaction. Scheduled for extractions U Cs and Ds and start phase I with an RPE with tongue guard and hooks for traction on U3s. They had extractions but no-showed the ortho start.

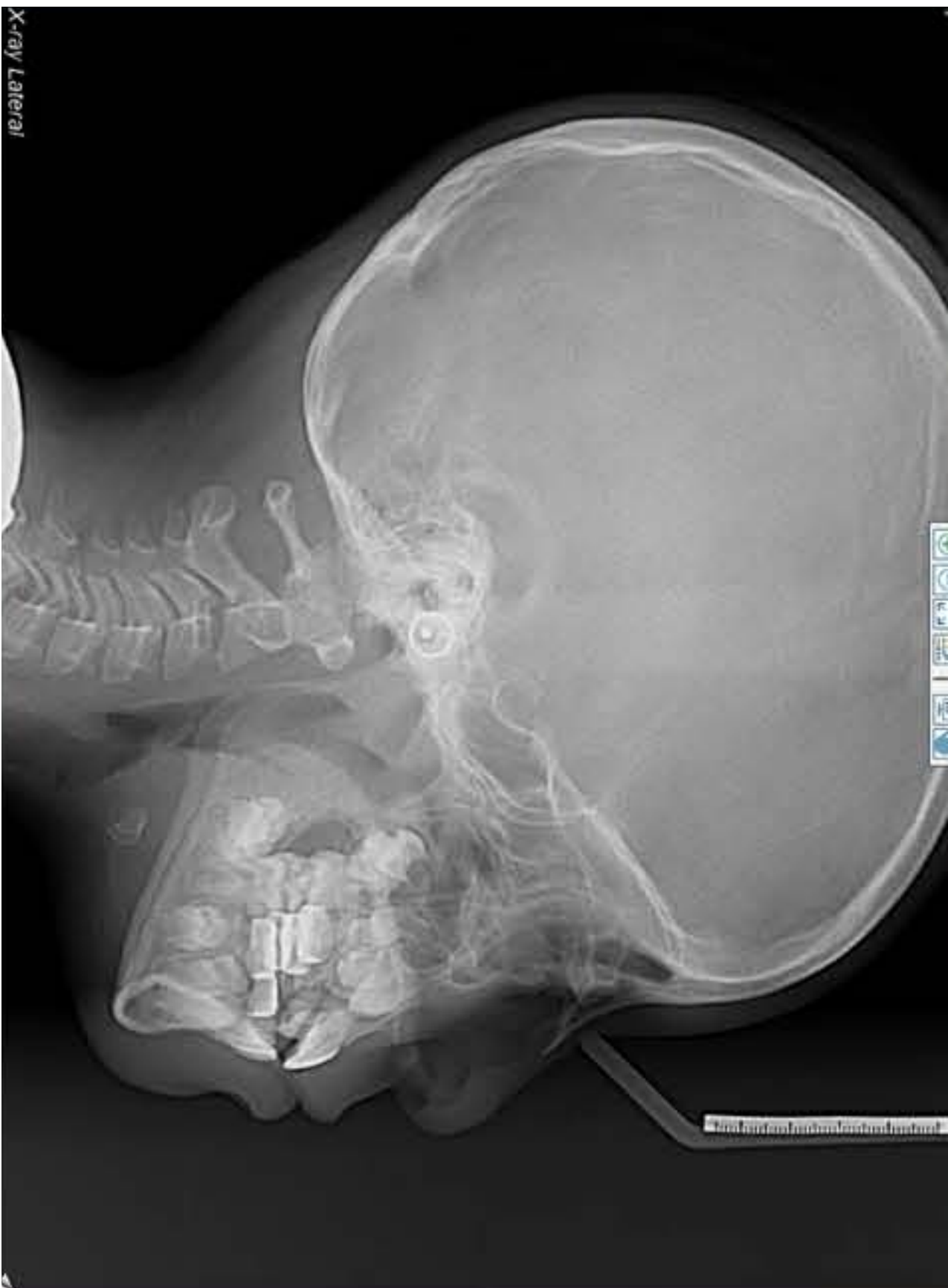X-ray Lateral

MA

Initial

1/15/2020

8y 6m





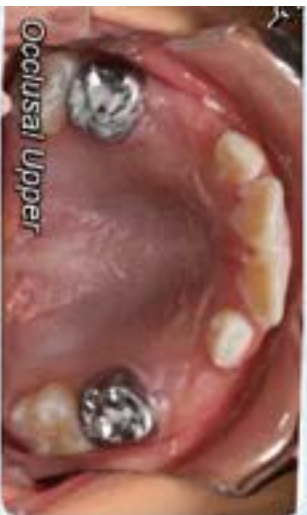Facial Profile



Facial Front

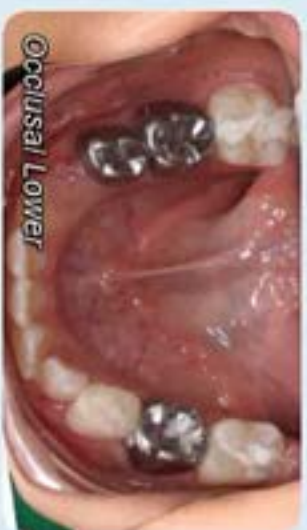

Facial Front Smiling

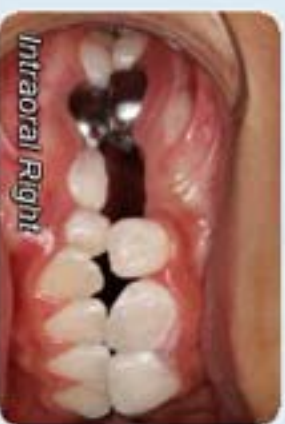

Occlusal Upper

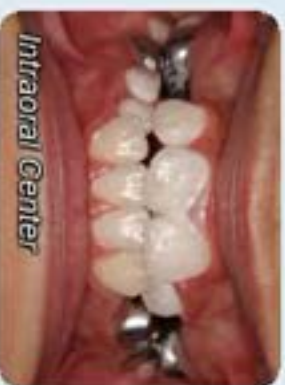MA Initial  
7/19/2020 9y 0m



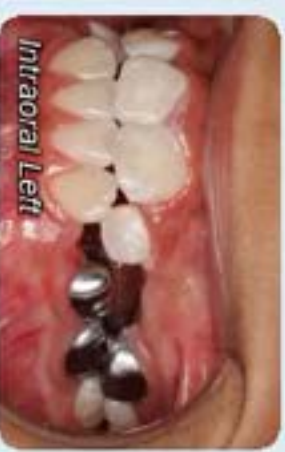Occlusal Lower



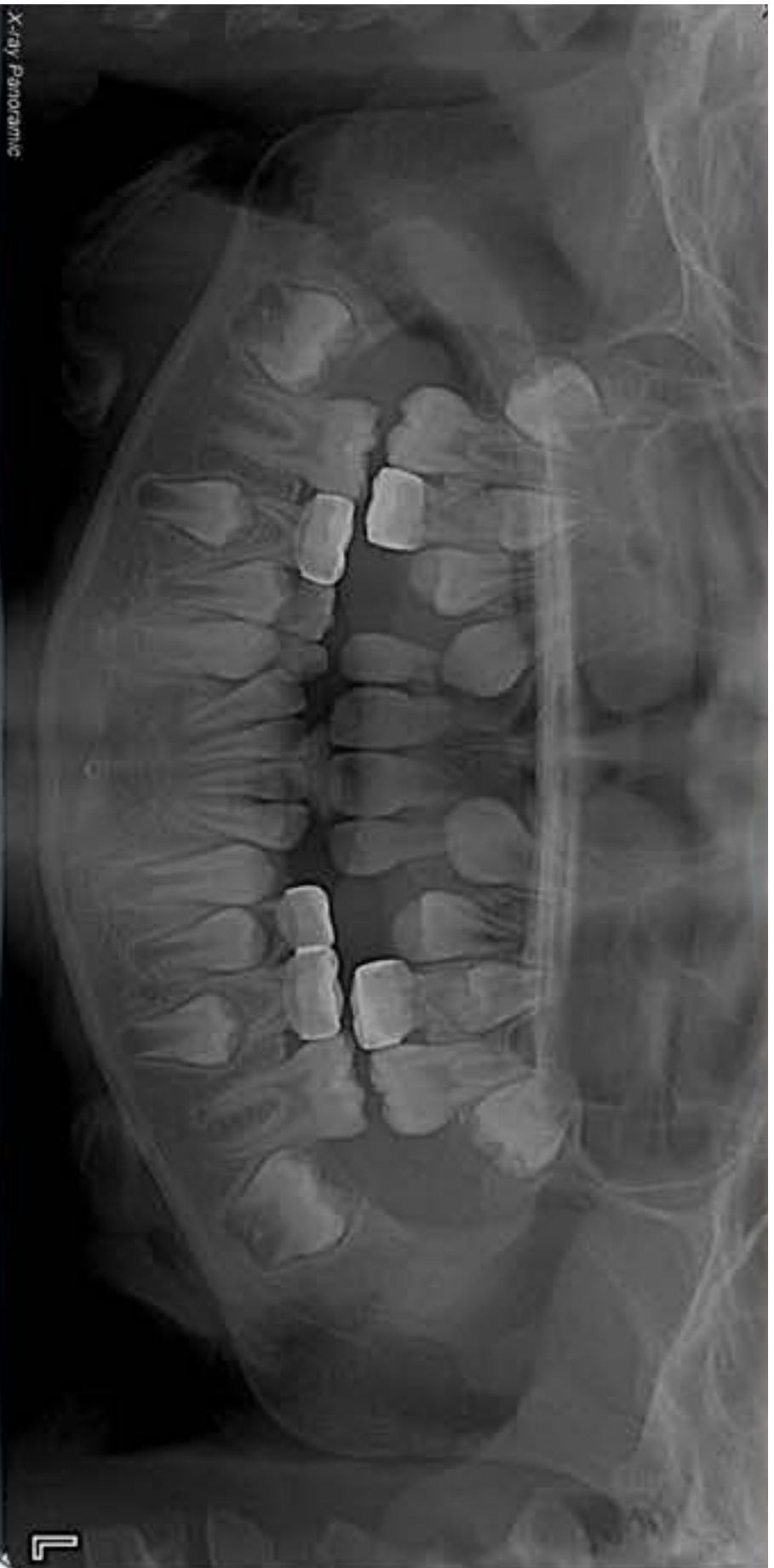Intraoral Right



Intraoral Center



Intraoral Left



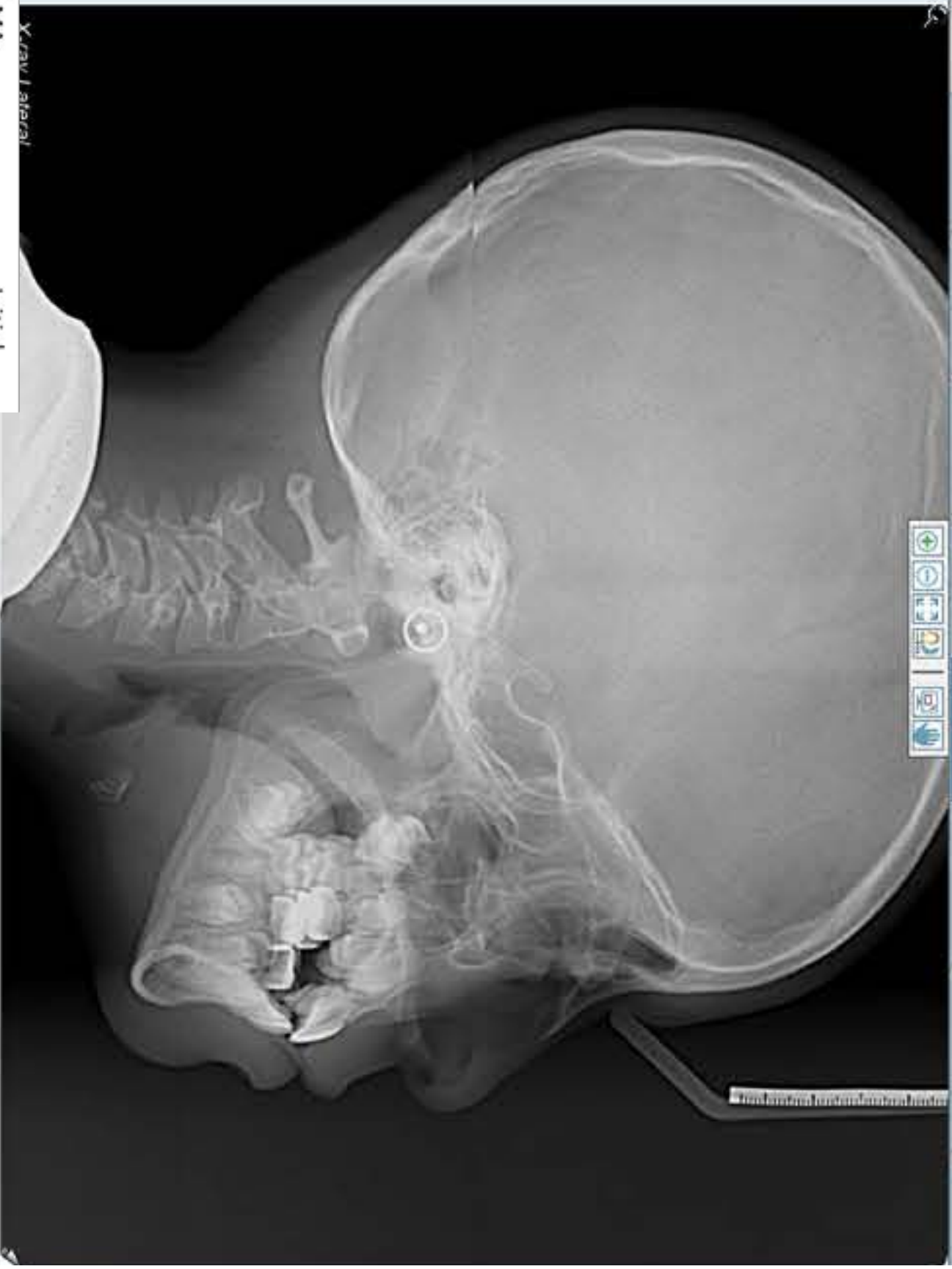MA

Initial

7/19/2020

9y 0m





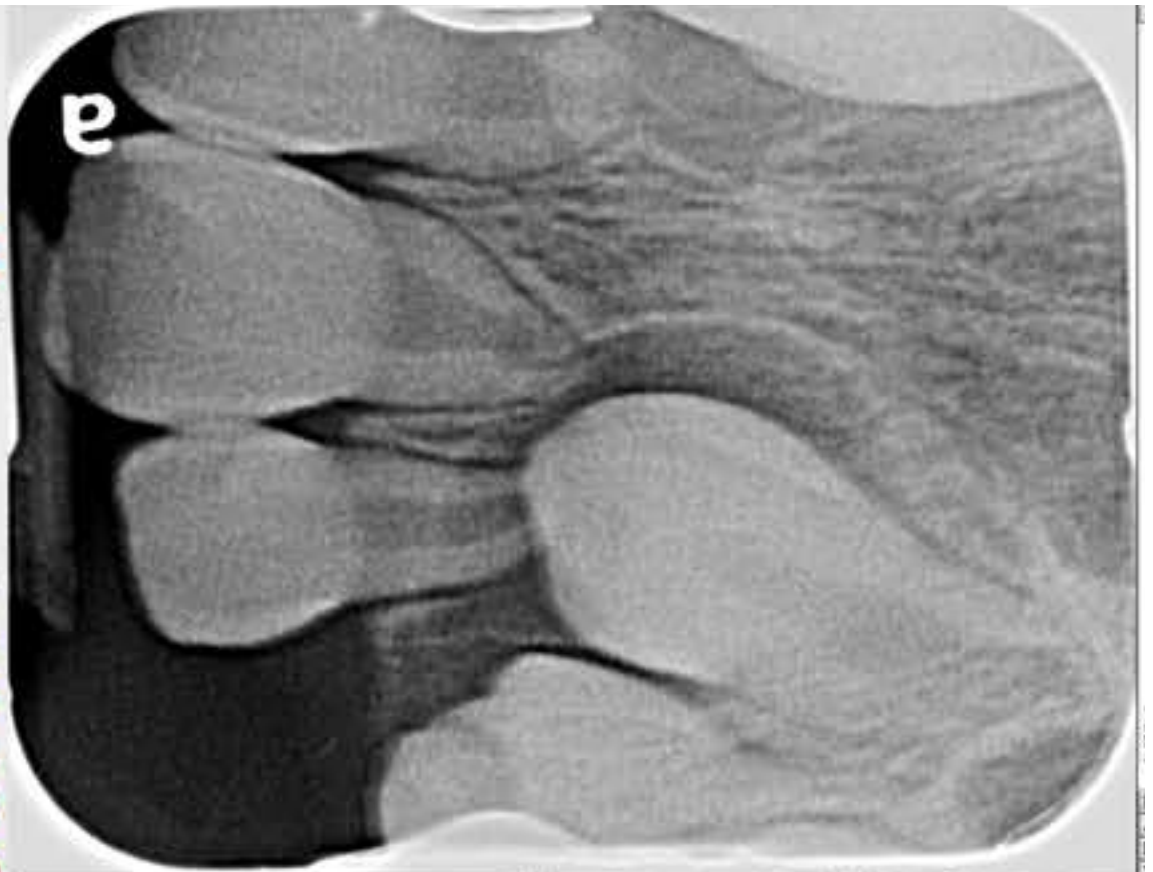
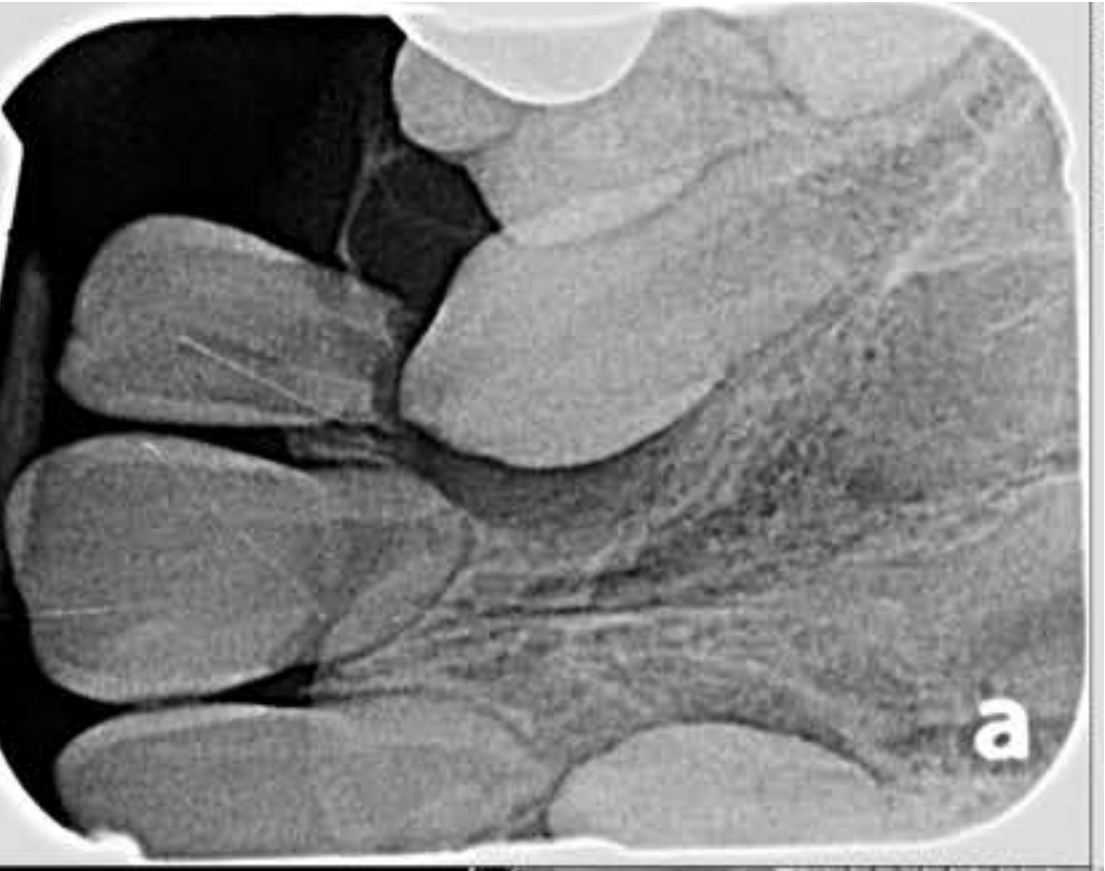MA

Initial

7/19/2020

9y 0m

Note increased root resorption upper incisors compared to ceph 6 mo ago.  
Emphasized need for ortho ASAP. Informed them U 1s will be lost at minimum.



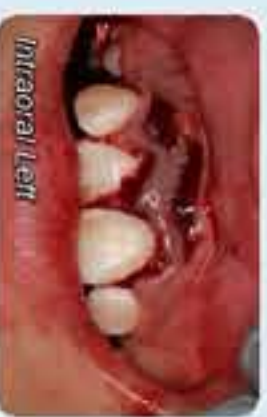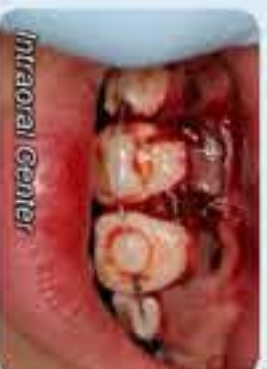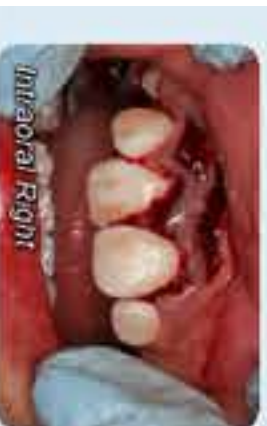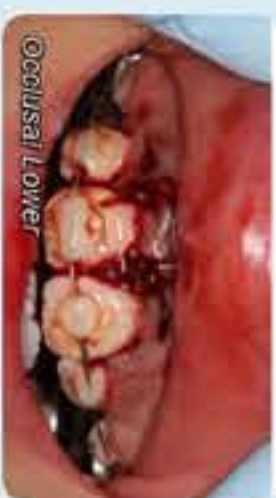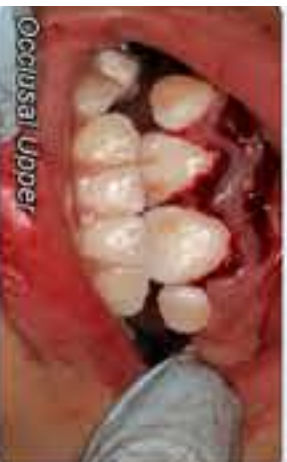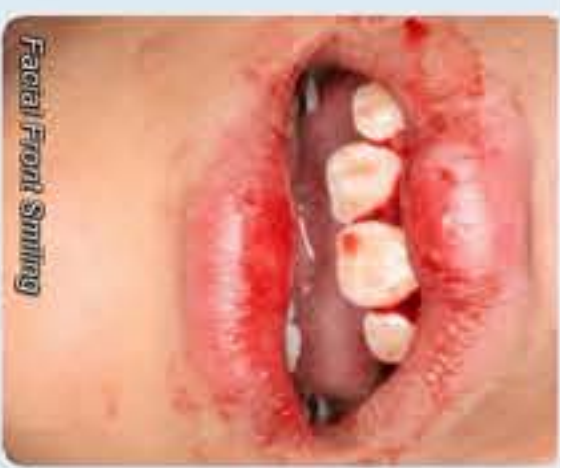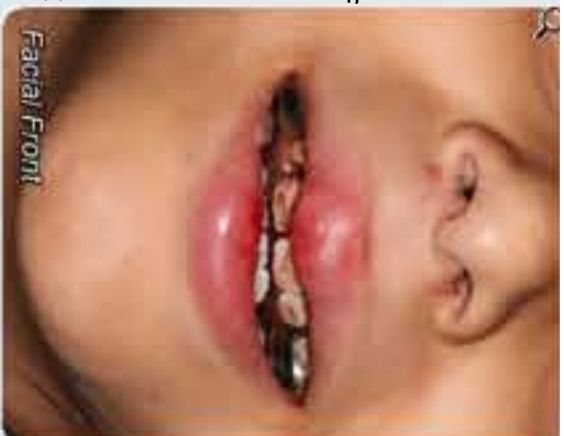MA

Initial

7/19/2020

9y 0m

Trauma #1. Hit another kid's head at school and has class 3 mobility U 2-2, all displaced from sockets. Alveolar fracture suspected d/t pattern of lacerations and fluctuant nature of alveolus but cannot be detected in radiographs. Treated as an alveolar fracture, which requires splint to stay in place for 4 weeks minimum. I seated incisors in the socket and moved them out of occlusion with finger pressure and bonded 014N splint passively and then and sutured lacerations and placed turbos on U 6s.



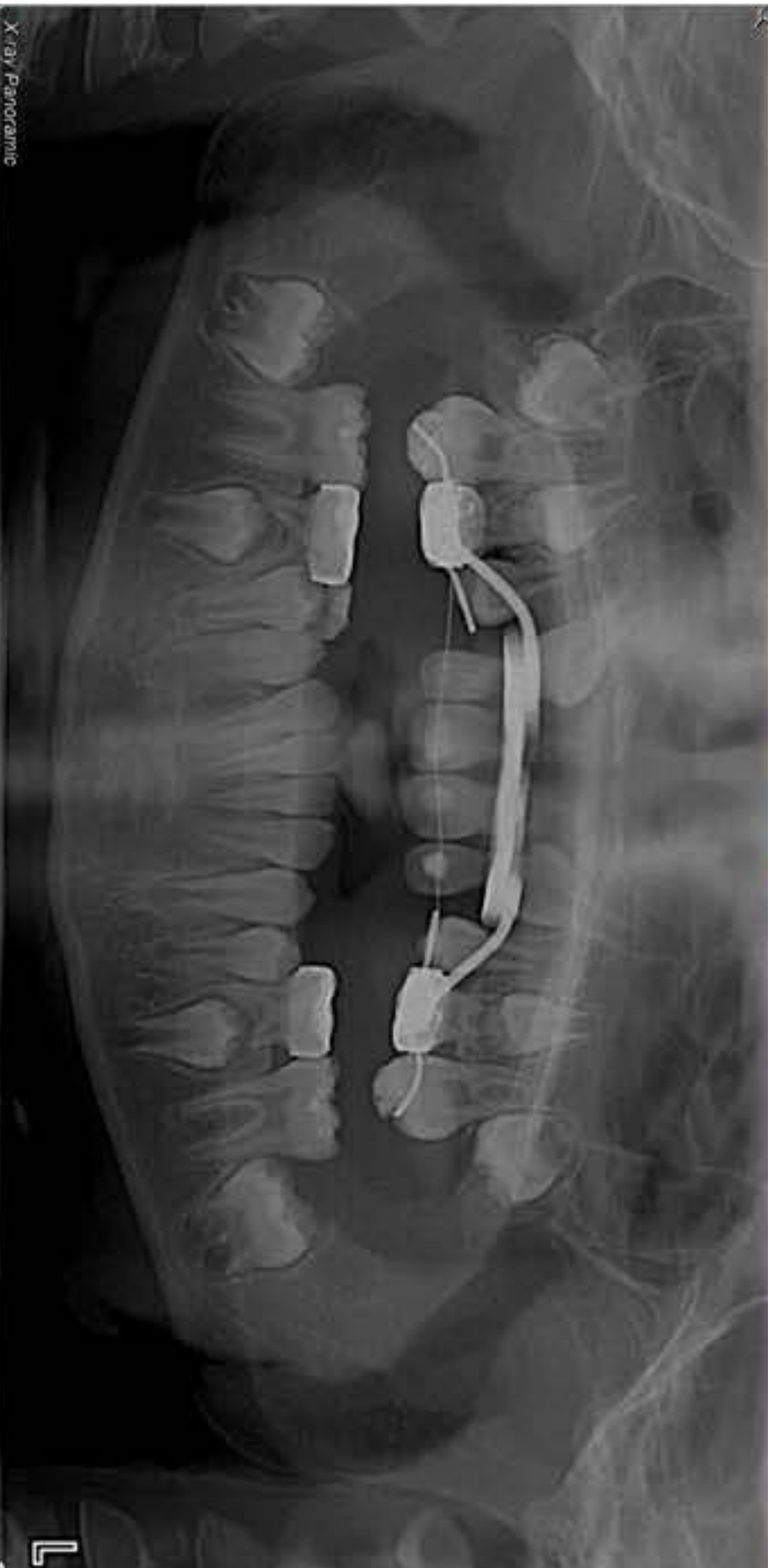MA

Initial

At this appointment, I learned they'd started phase I 5 months ago elsewhere. RPE is in and mom believes phase I is complete.

12/21/2020

9y 6m



X-ray Panoramic

MA

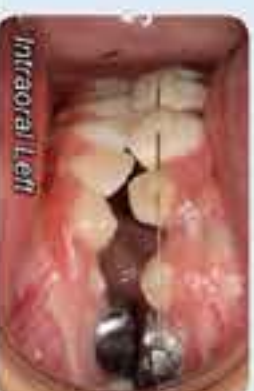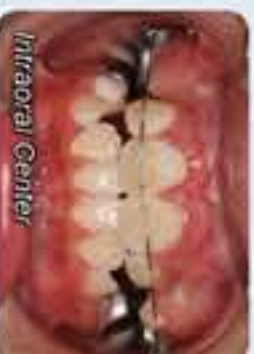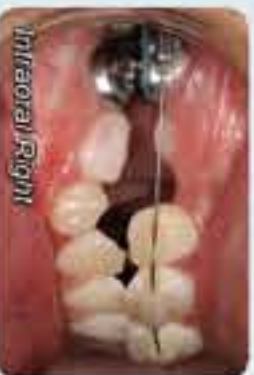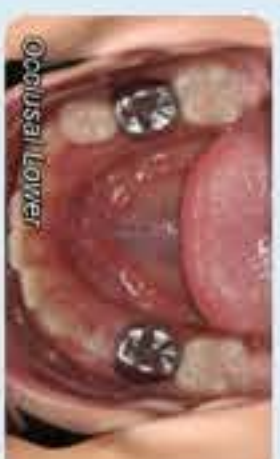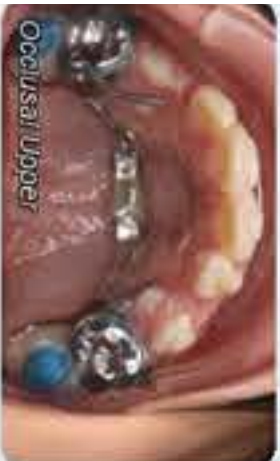Initial

12/21/2020



9y 6m

L



MA

Initial



1/16/2021

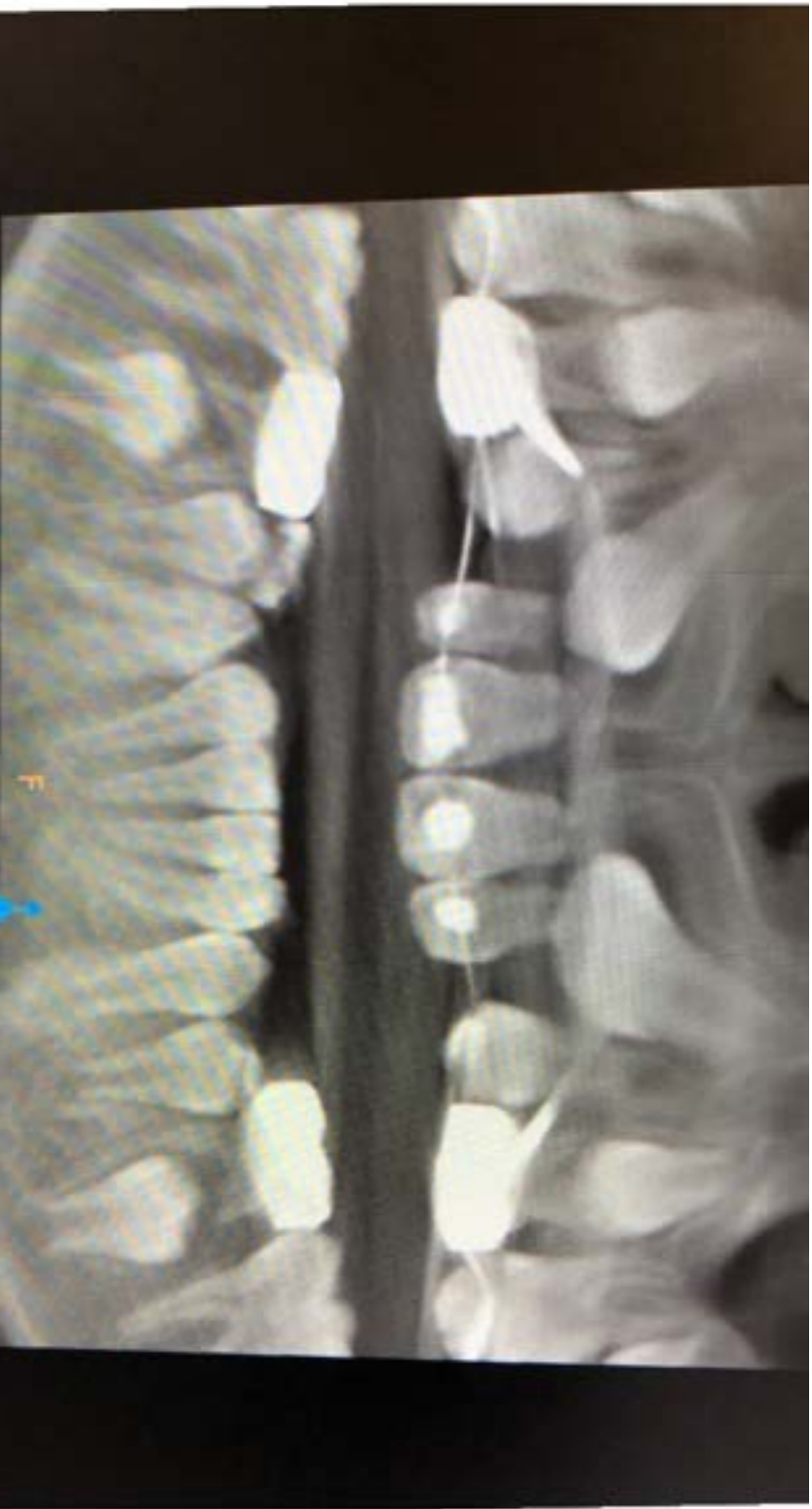9y 7m

Trauma #2 happened only a couple weeks later. Luckily she was splinted but d/t mobility at follow up decided to leave splint on longer. At this appointment, mom told me she was unhappy at other ortho office and wants to transfer to me. Referred to perio for prognosis U 2-2 and CBCT before completing treatment plan.

CBCT taken. Perio consult: U 2-2 prognosis deemed hopeless.

Tx plan:

Remove RPE and place TPA. Perio to expose and bond U 3s and extract U 2s. When U 3s are fully erupted in arch, will make decision re: extraction of 1<sup>st</sup> or 2<sup>nd</sup> premolar extraction on lower arch. U 3s will be subbed for U 2s and U 1s will stay splinted but not bonded to maintain tissue for future implant esthetics.



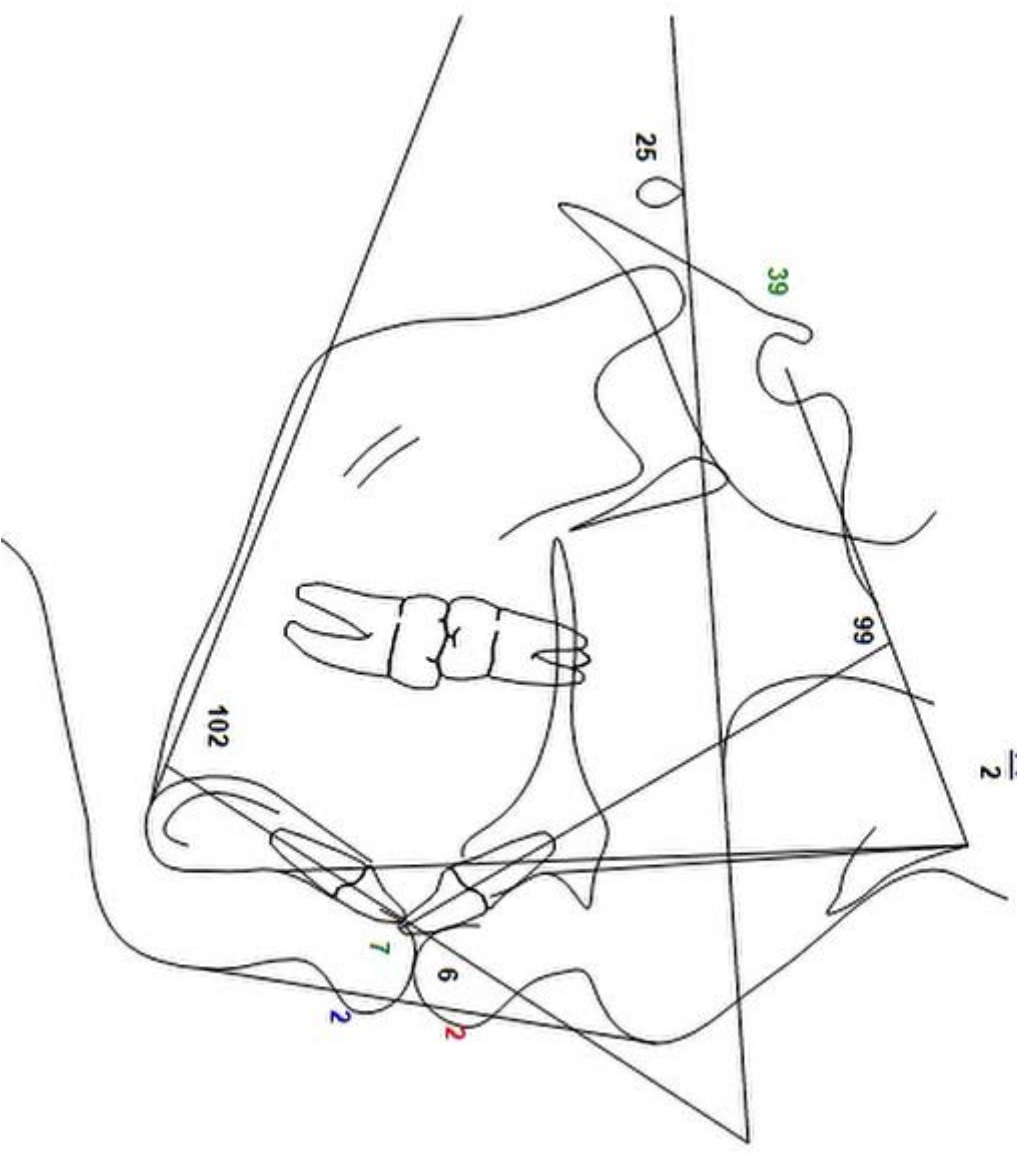
MA

Initial

1/16/2021

9y 7m

73  
74  
2



MA

Initial

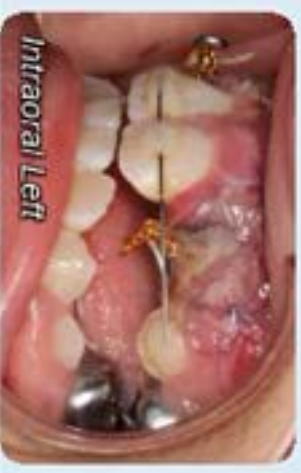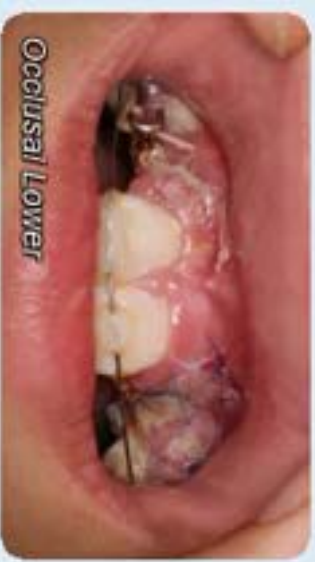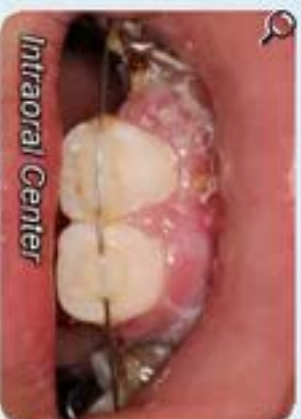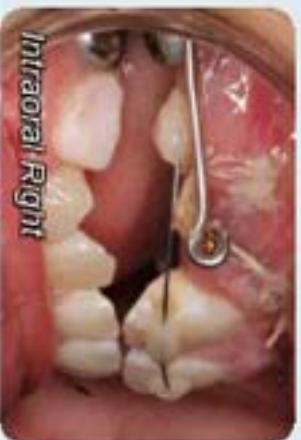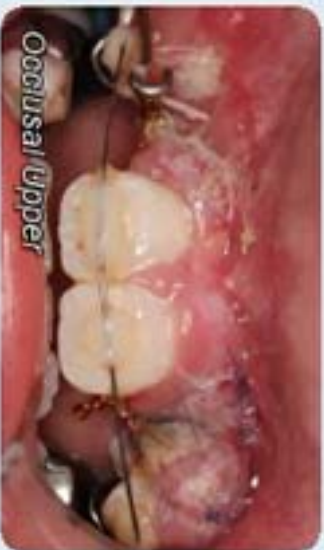1/16/2021

9y 7m



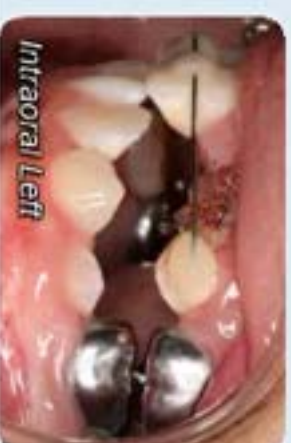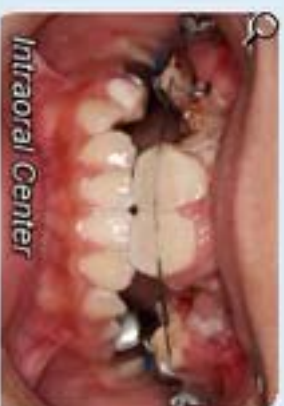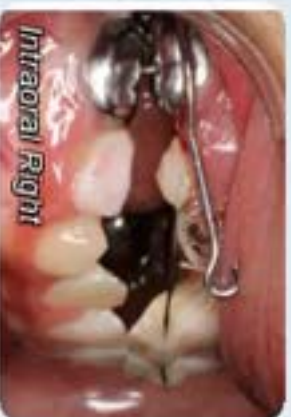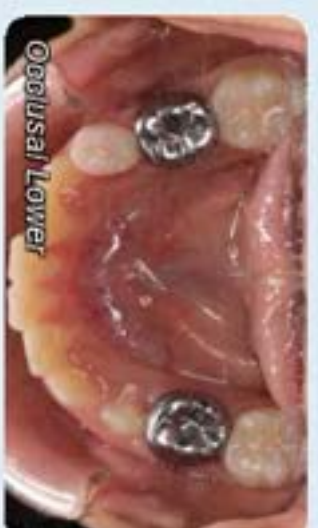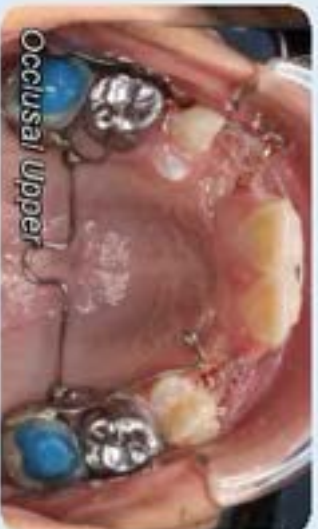2/25/2021

Delivered TPA. Exposed and bonded U3s and extracted U2s. Father passed away shortly after.



Progress 3/6/2021

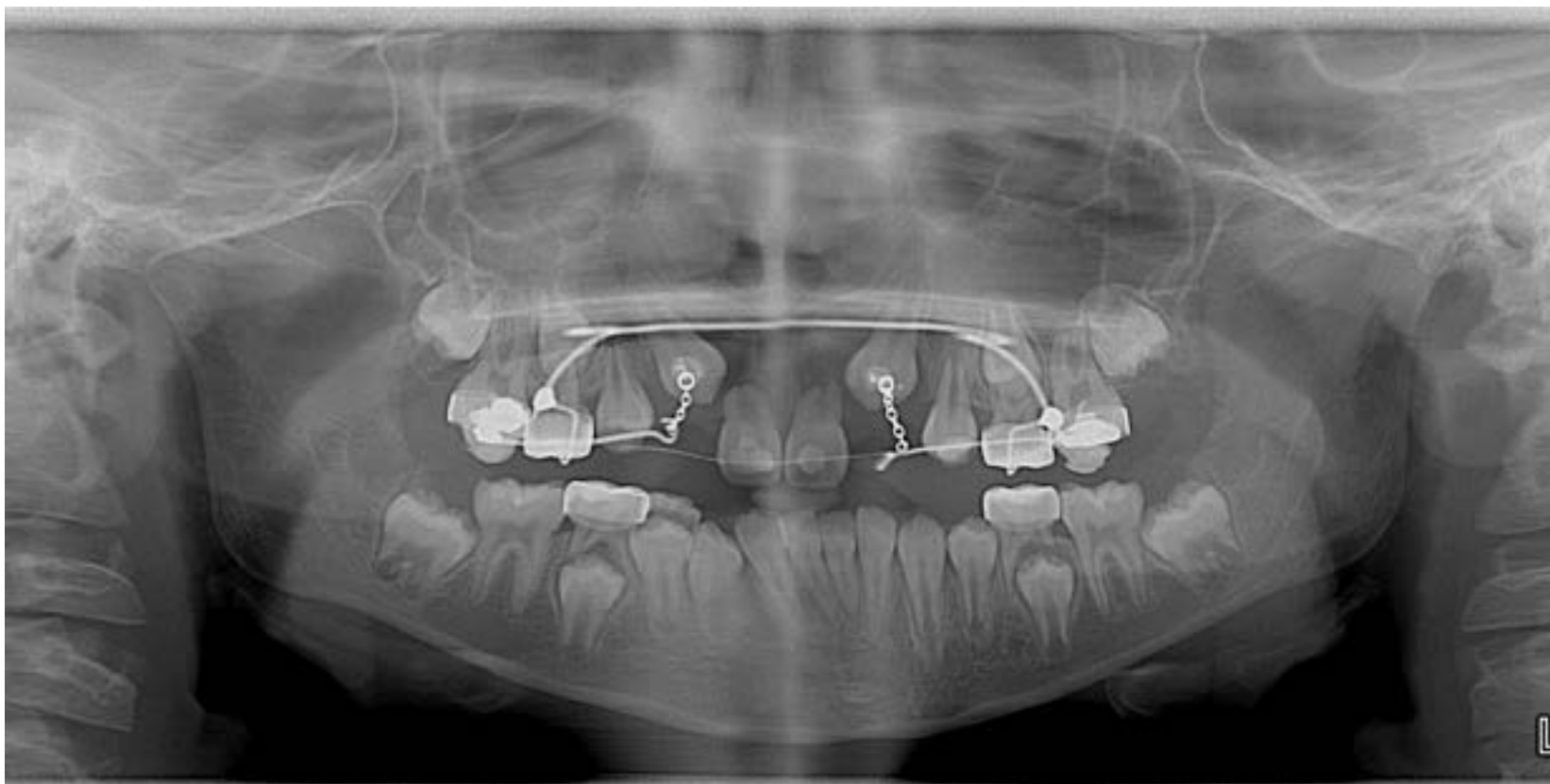
Traction U 3s, splint remains U 1s. Added to turbos.

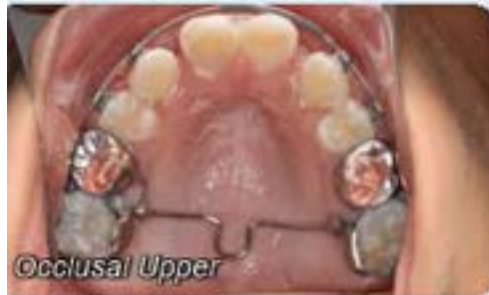
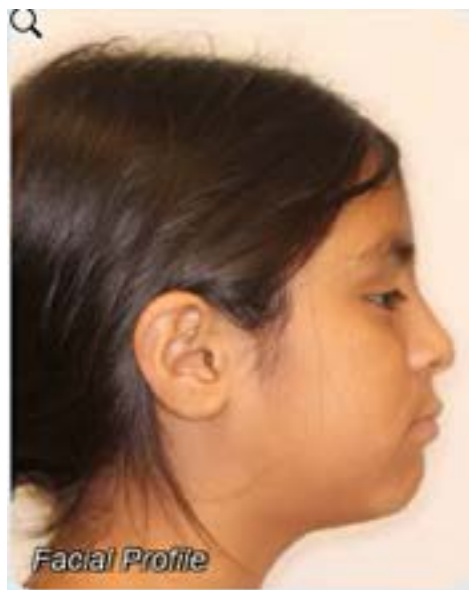
# Slides 19-32

(#2 is #19)

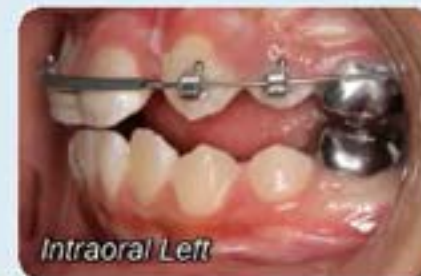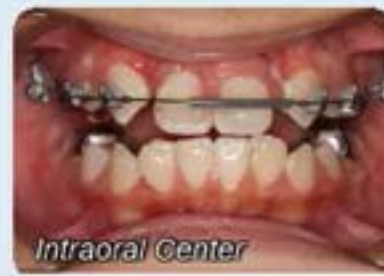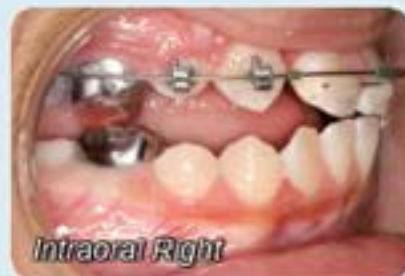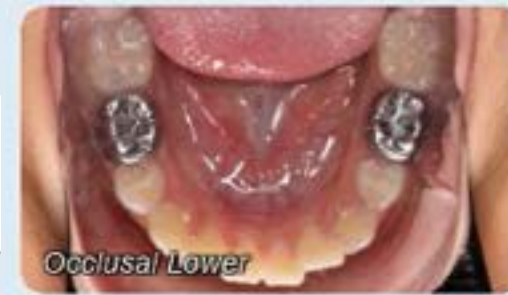# Progress 3/6/2021



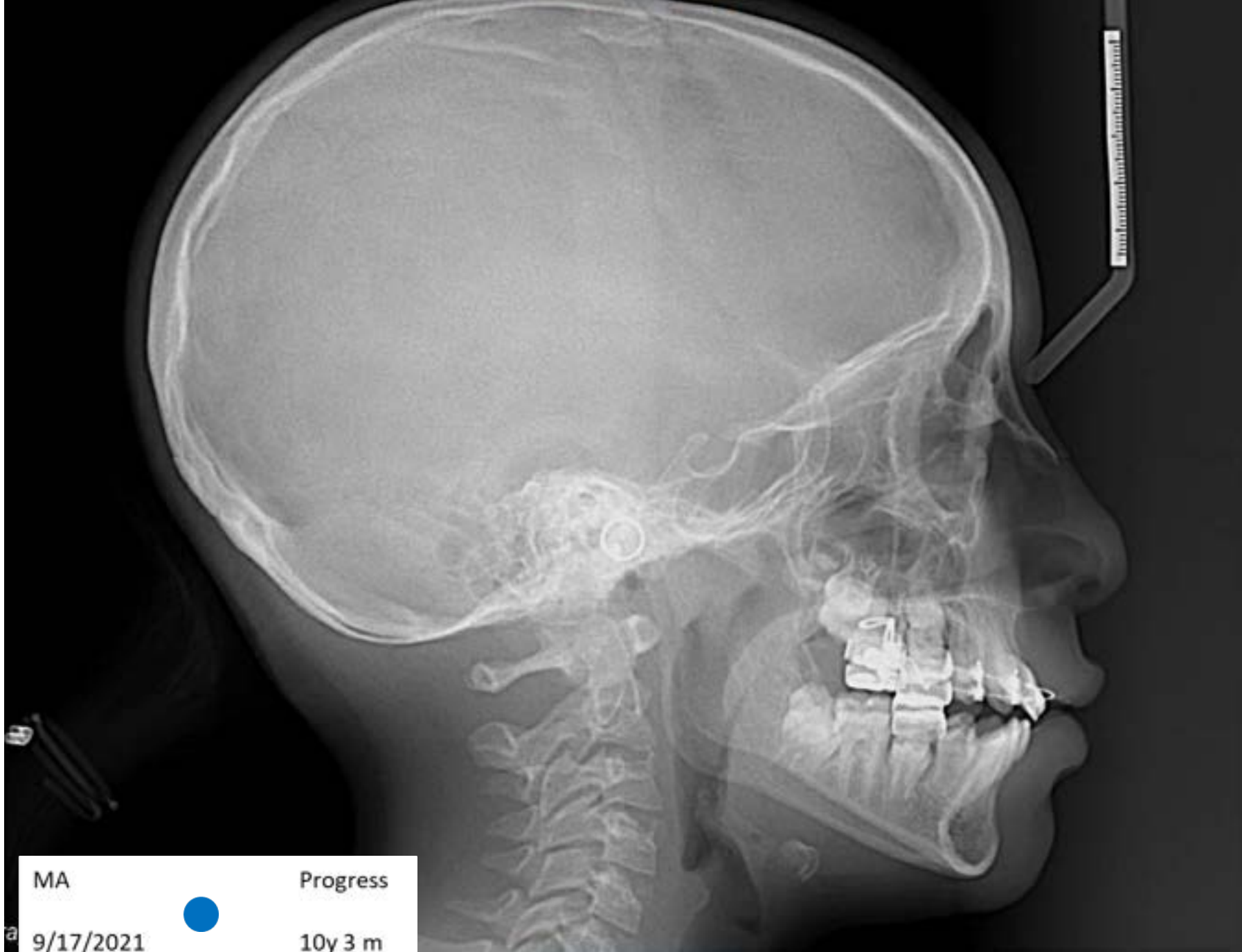


MA  
9/17/2021

Progress  
10y 3 m



Bonded U 3s and 4s for initial alignment, bypassing U1s

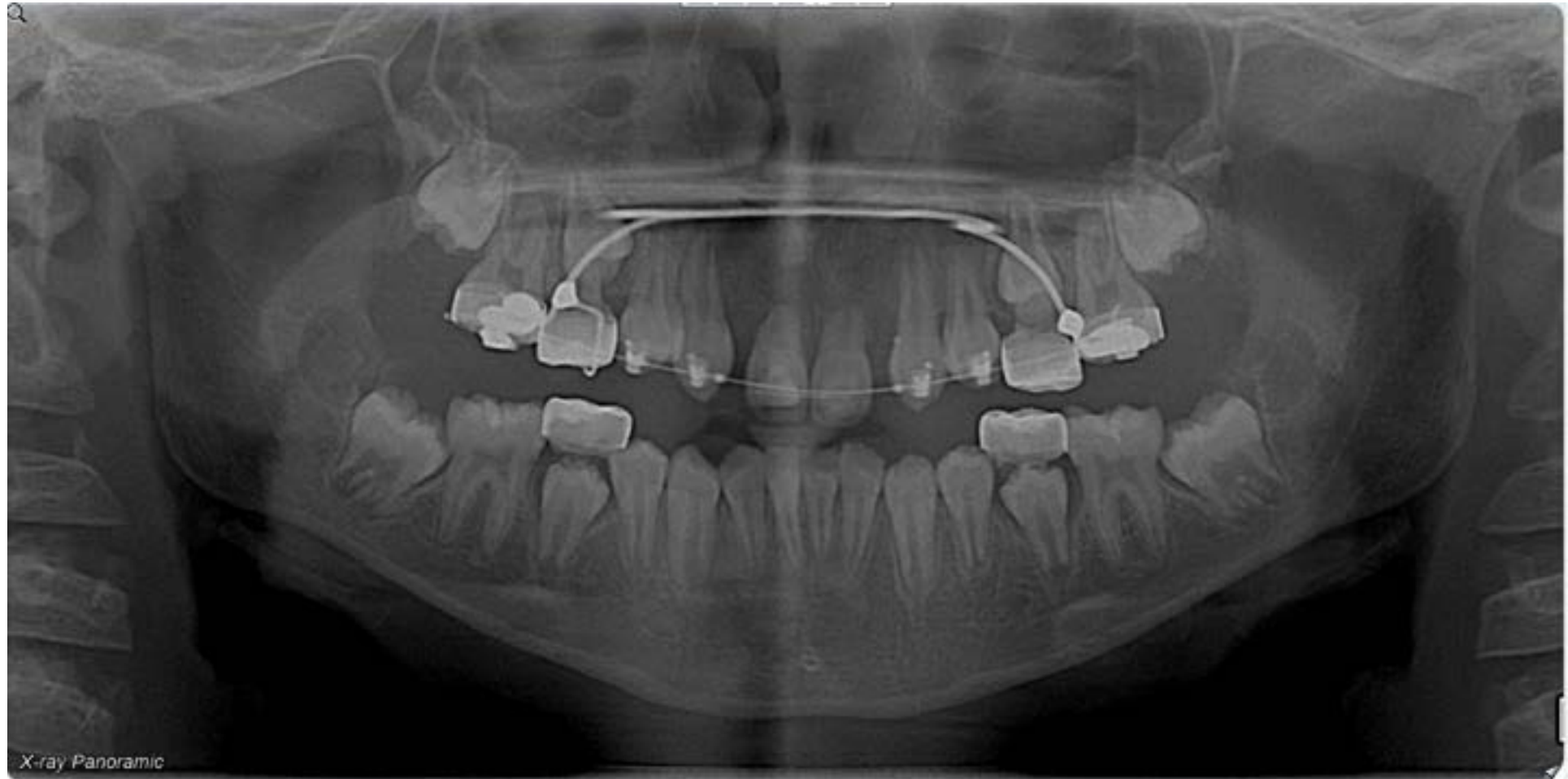

MA  
9/17/2021

●

Progress  
10y 3 m

MA  
9/17/2019



MA

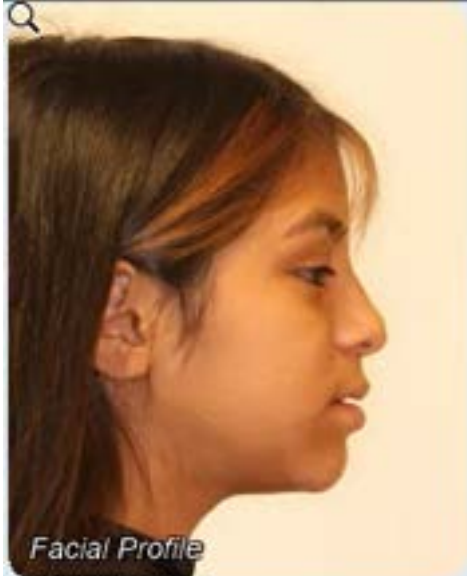

9/17/2021

Progress

10y 3 m

L7s impacting. Referred for extraction all remaining primary teeth.



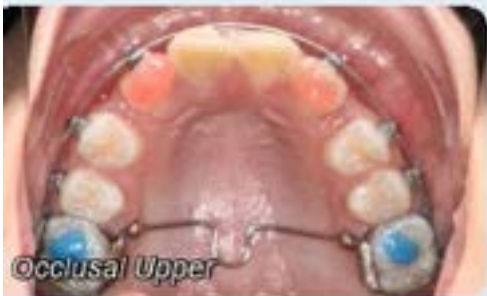Facial Profile



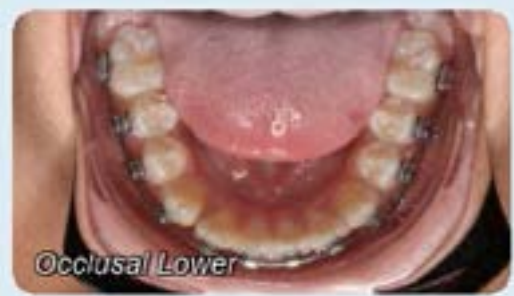Facial Front



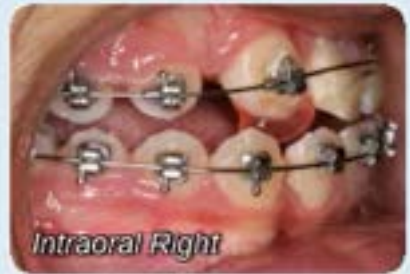Facial Front Smiling



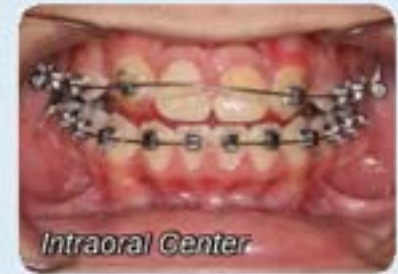Occlusal Upper



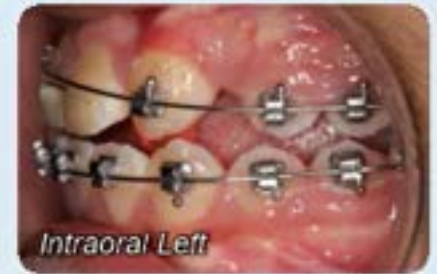Occlusal Lower



Intraoral Right



Intraoral Center



Intraoral Left

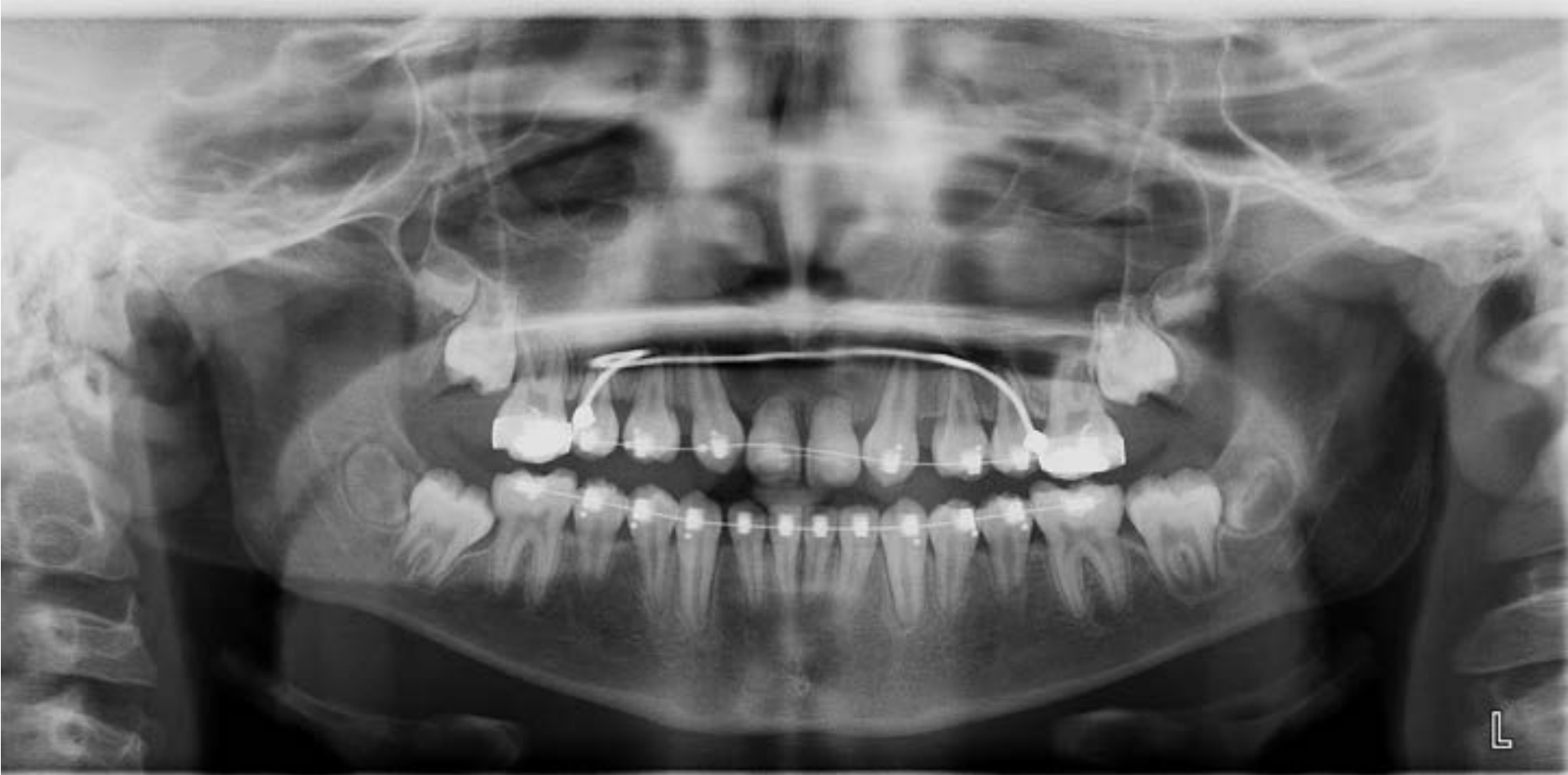MA

Progress



8/20/2022

11y 2 m



MA

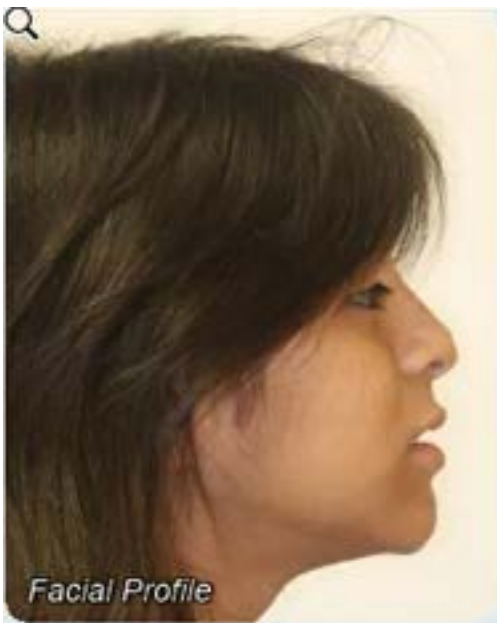8/20/2022



Progress

11y 2 m

LR 7 still impacted. Patient's appointments more sporadic d/t mom's schedule and tight finances. Made decision to ext L5s due to shorter roots but patient d/n get extractions for a year after referred.



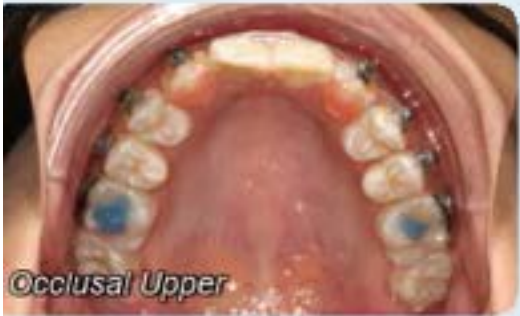Facial Profile



Facial Front

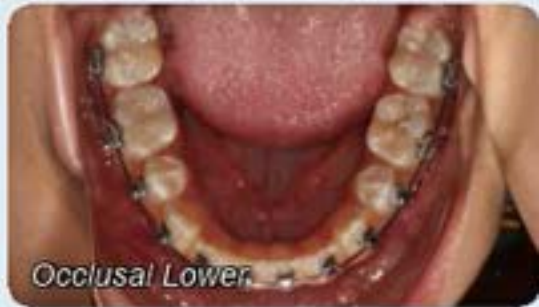

Facial Front Smiling

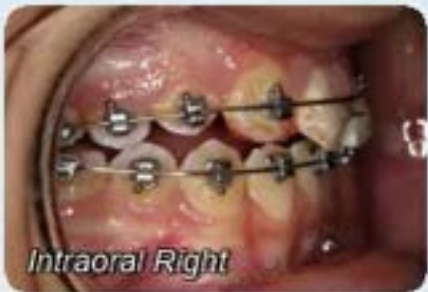

Occlusal Upper

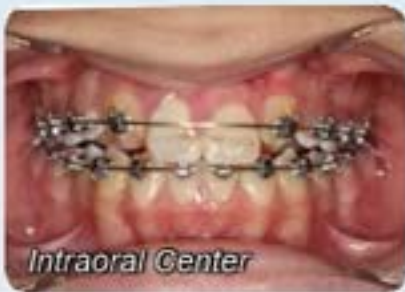MA	Progress
4/19/2024	12y 10m



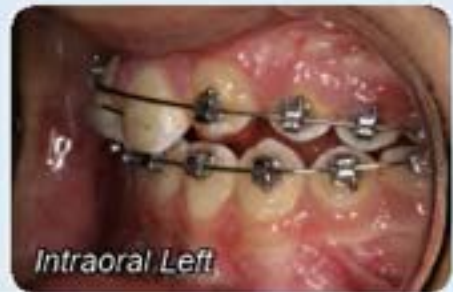Occlusal Lower



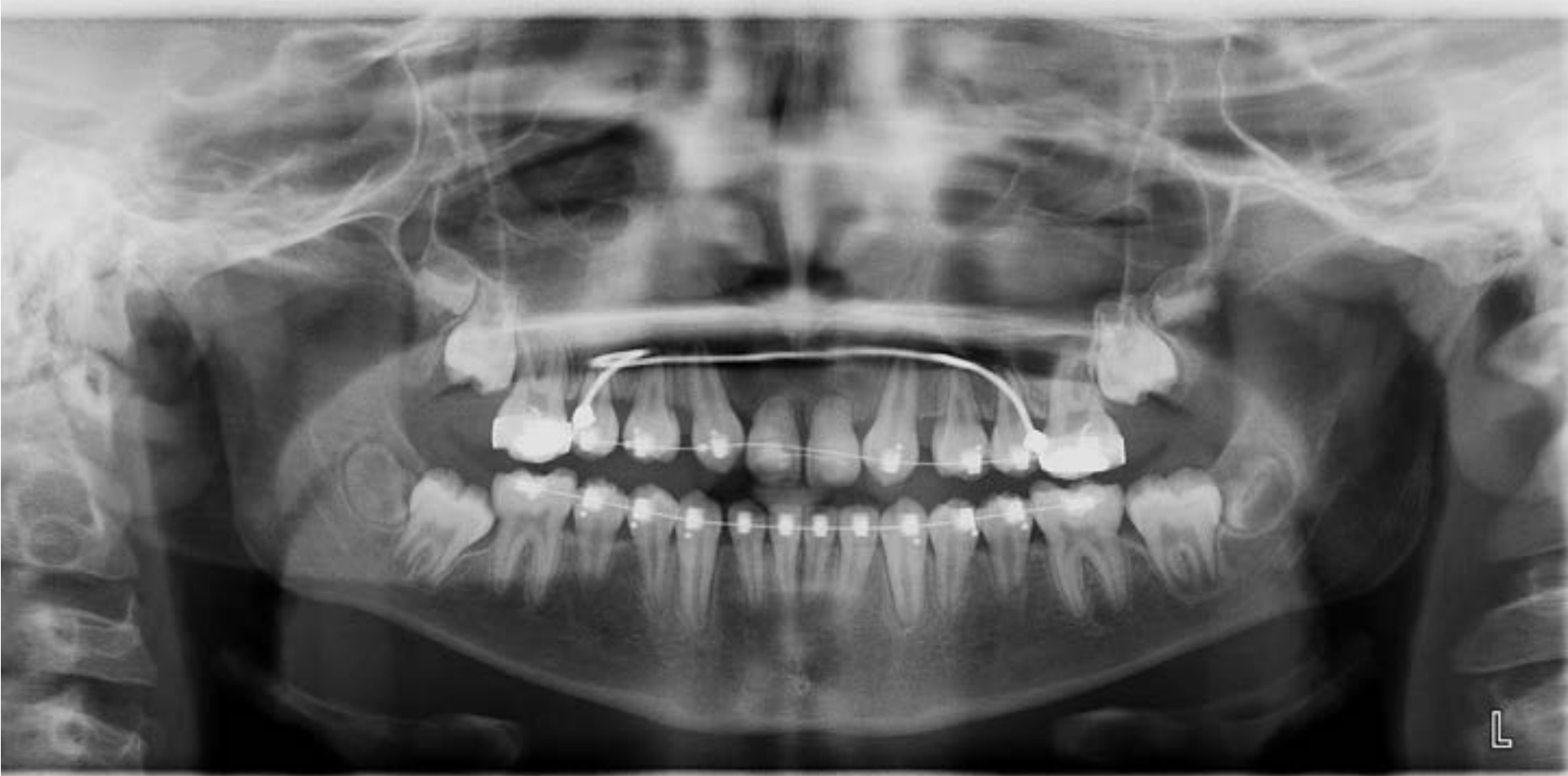Intraoral Right



Intraoral Center



Intraoral Left



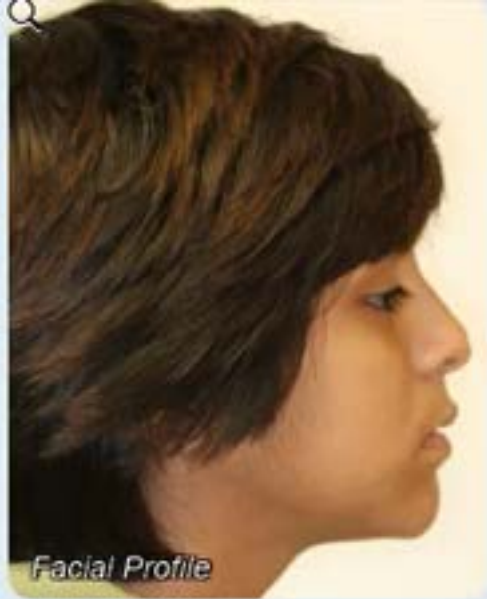MA

4/19/2024



Progress

12.10



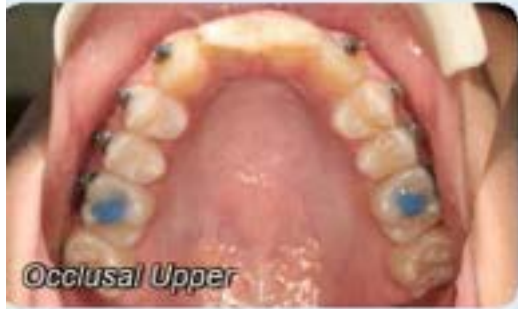Facial Profile



Facial Front



Facial Front Smiling



Occlusal Upper

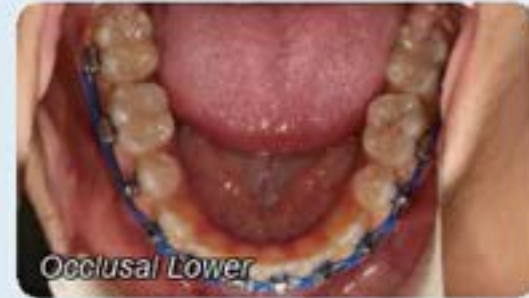MA

Progress

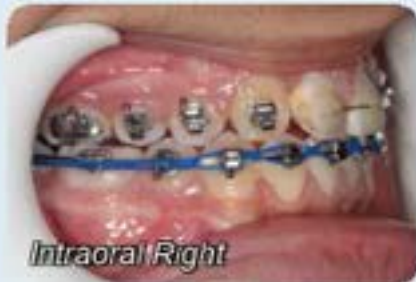12/1/2024



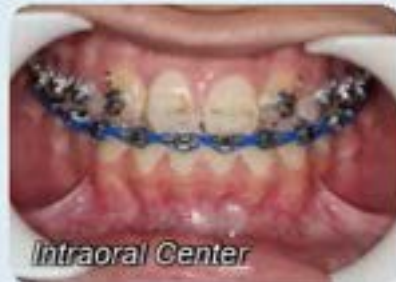13y 6m



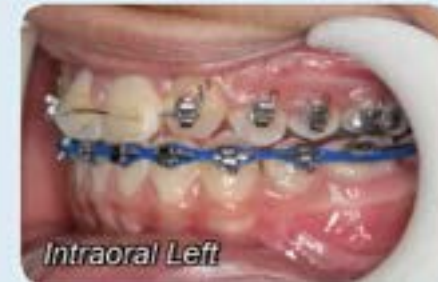Occlusal Lower



Intraoral Right

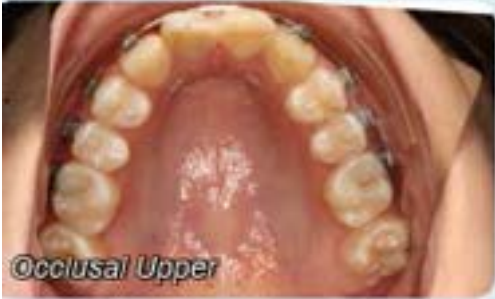
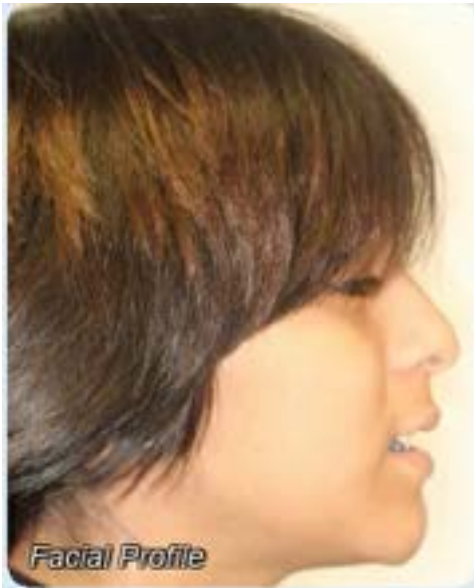

Intraoral Center



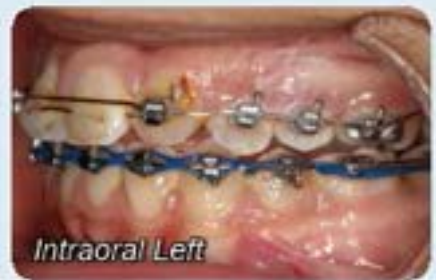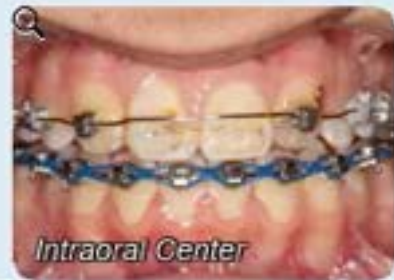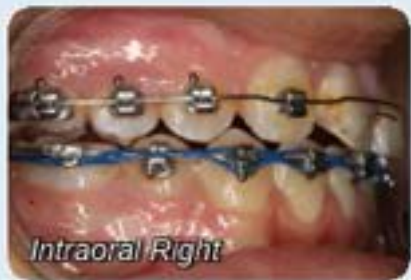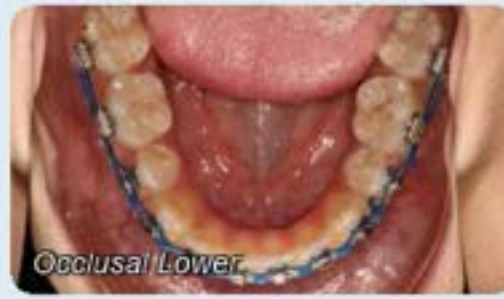Intraoral Left

Reshaped U 3s to be U 2s and rebonded with U 1s brackets. Wearing class III

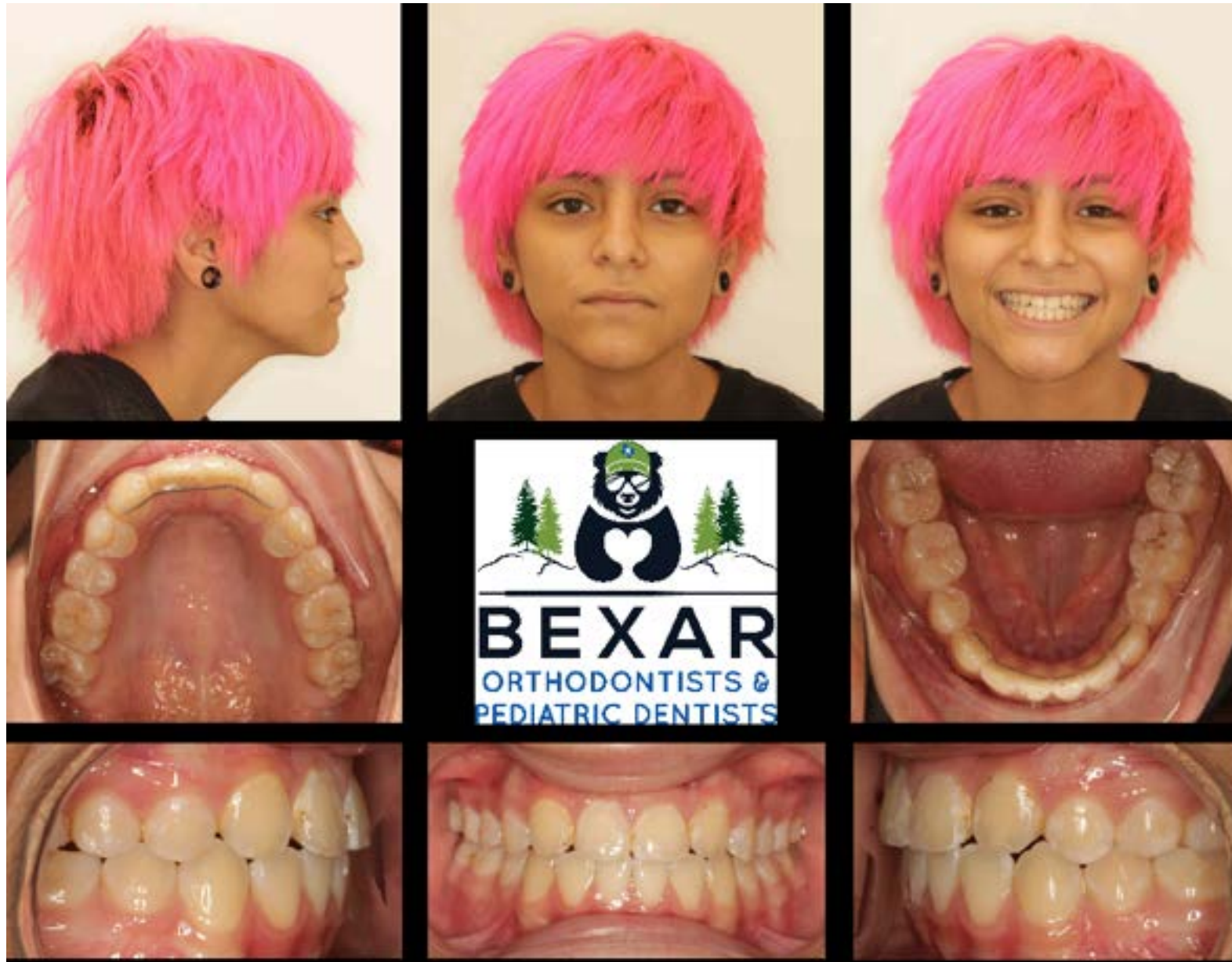

MA  
1/26/2025

Progress  
13y 7m



Detailing while bypassing U 1s



MA

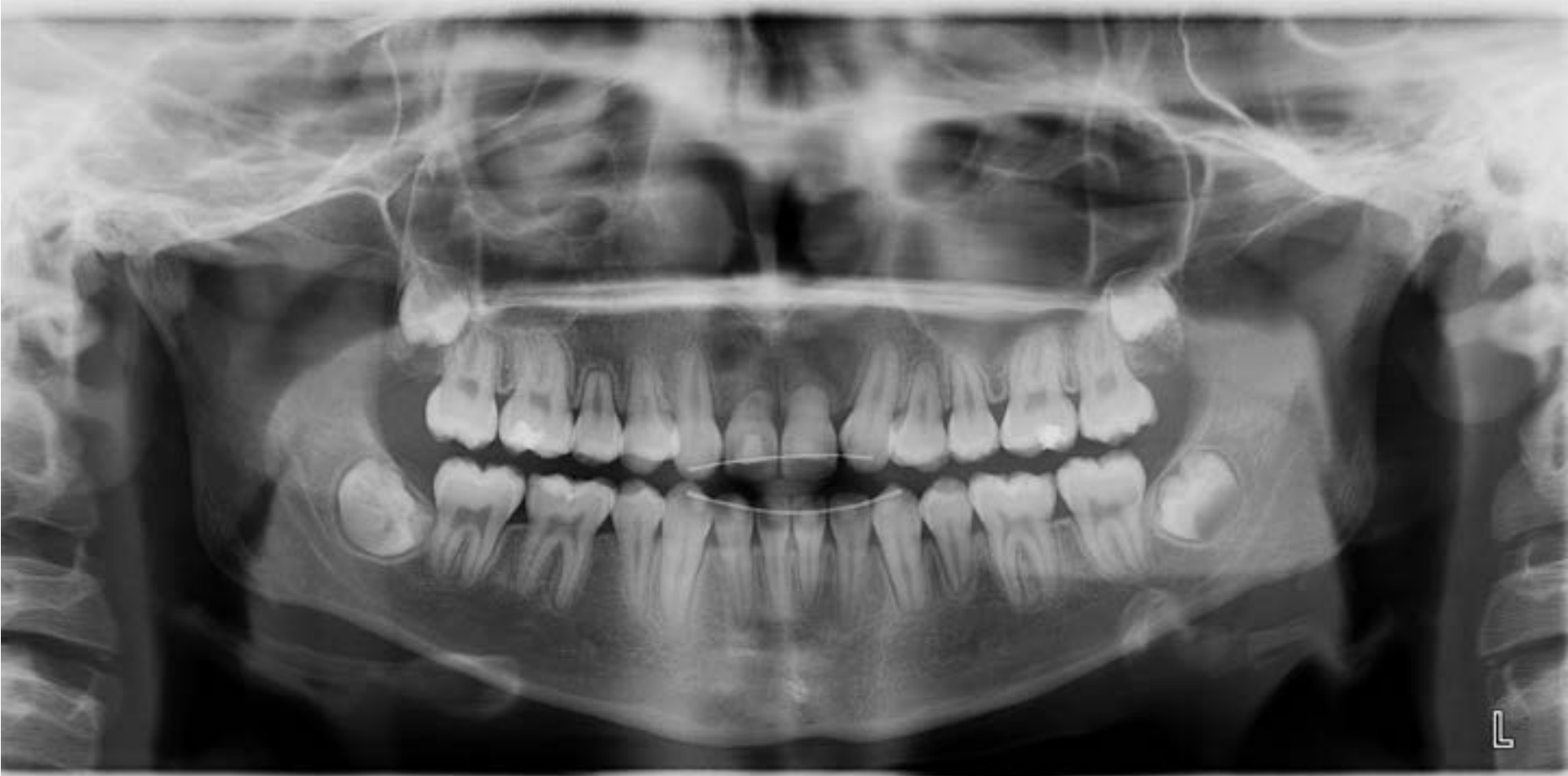

Final

9/27/2025

14y 3m

Debond day after she went missing for 7 months and came back with a new look. Noted several carious lesions. Retained with lingual bonded retainers (MX to act as a splint to retain U 1s as long as possible) and U/L Essix retainers. Pt know she will benefit from implants U 1s and veneers U 2s when growth is complete.



MA

9/27/2025



Final

14y 3m

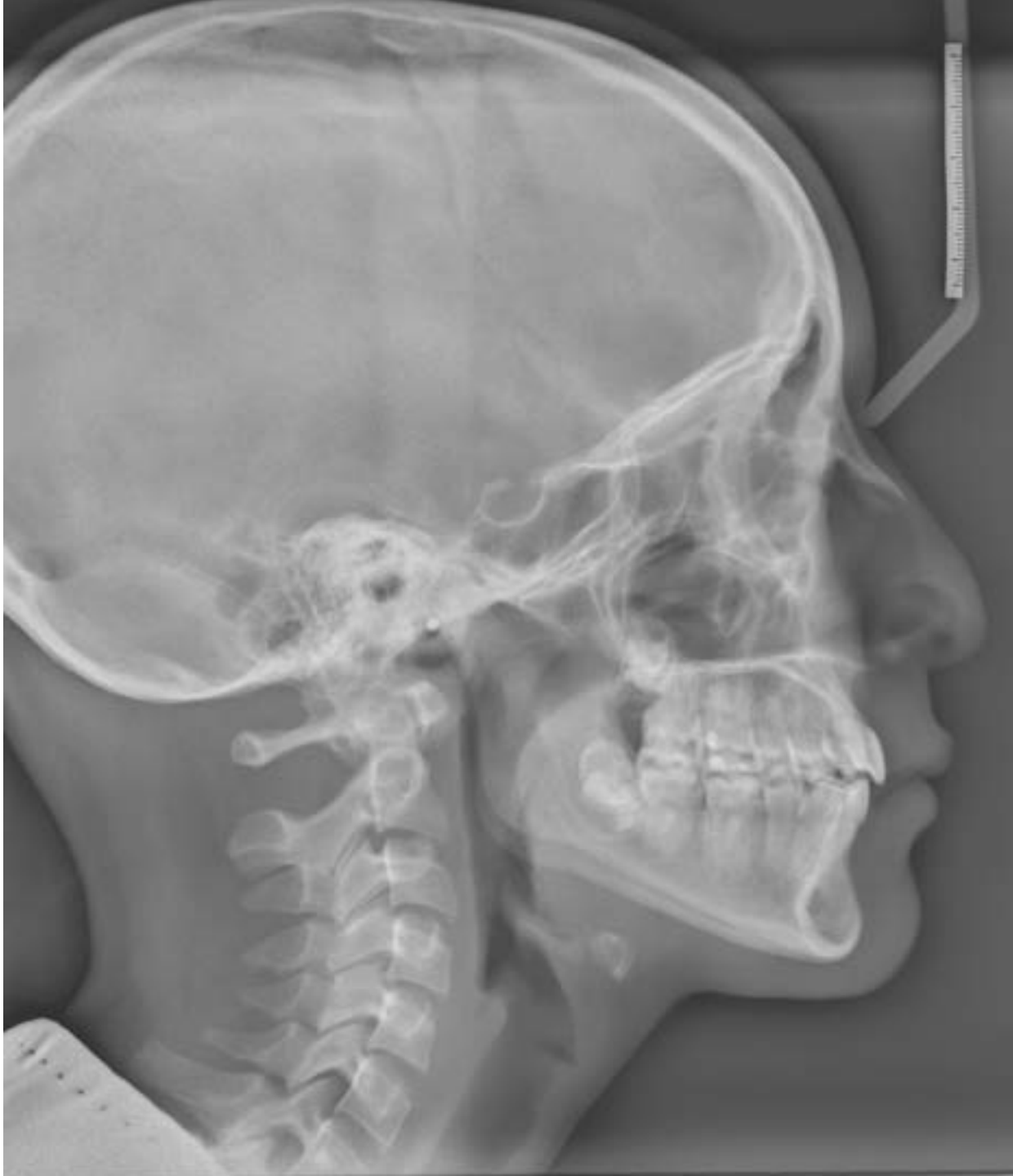MA

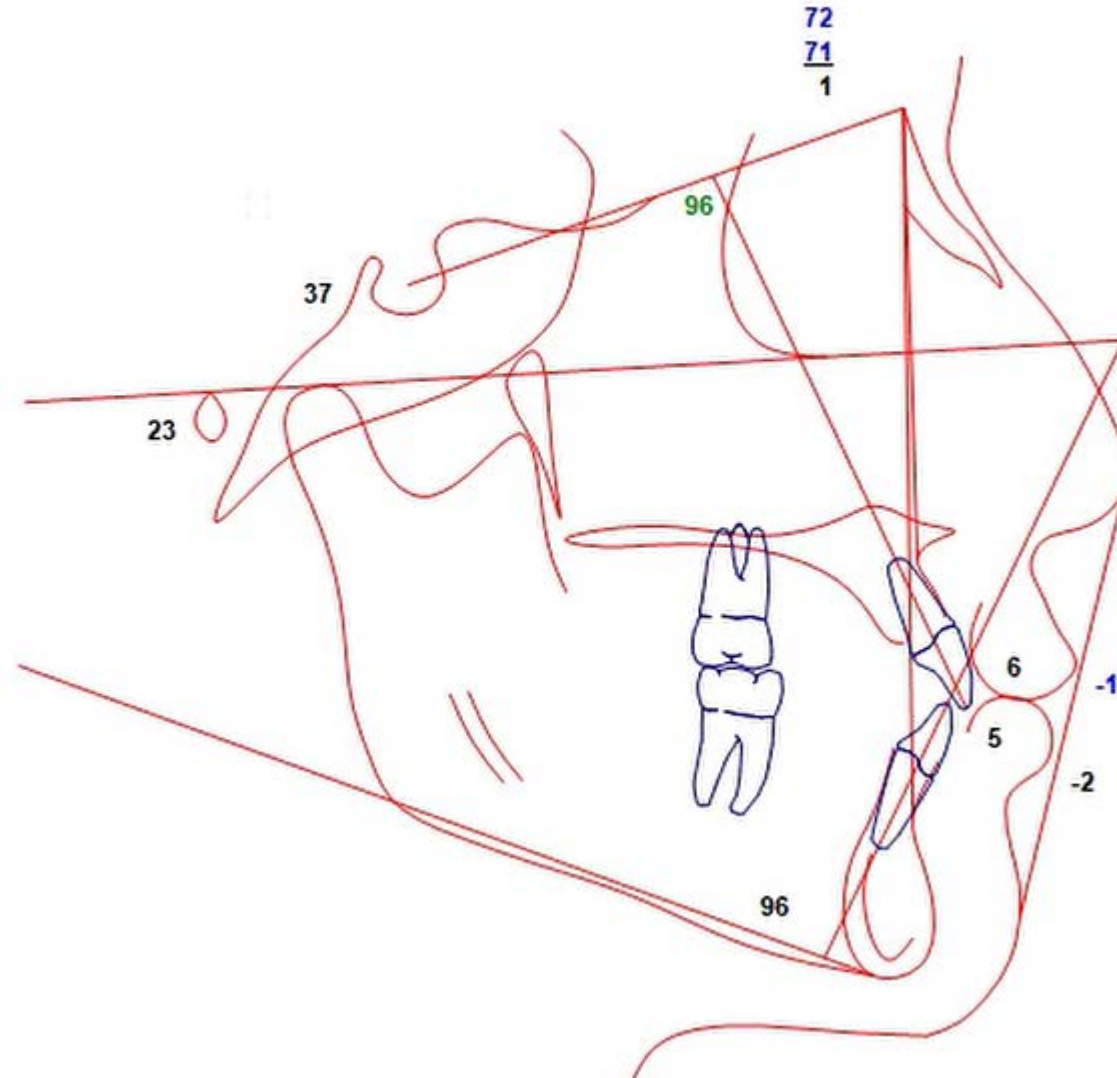
9/27/2025



Final

14y 3m





MA

9/27/2025



Final

14y 3m

I moved offices and got a new ceph machine last year, hence, no superimposition.